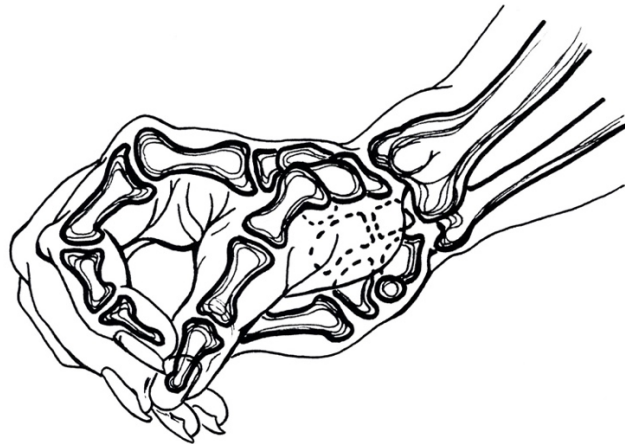
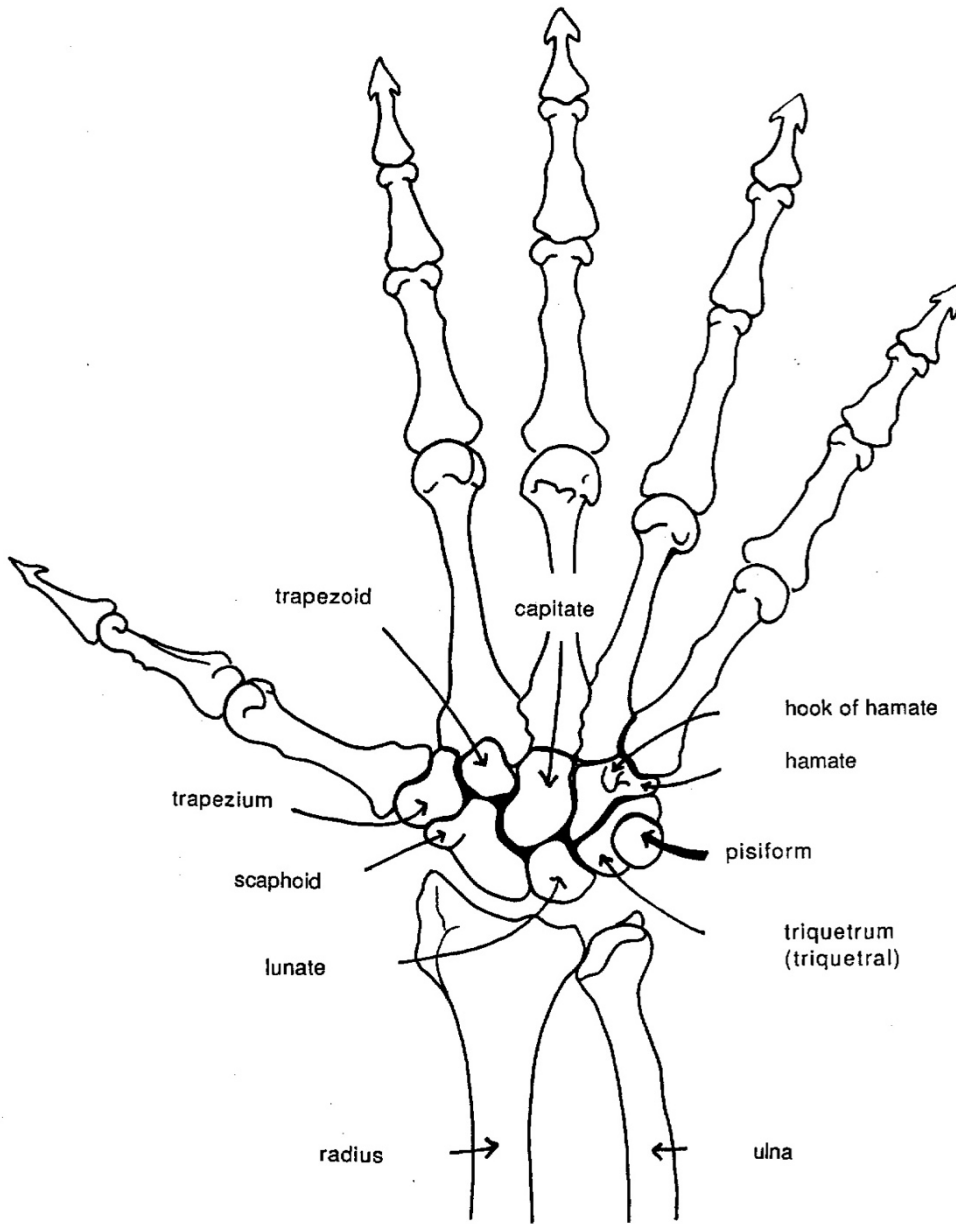


## **ILLUSTRATIONS OF THE WRIST AND HAND - BONES, MOVEMENT AND MUSCLES**

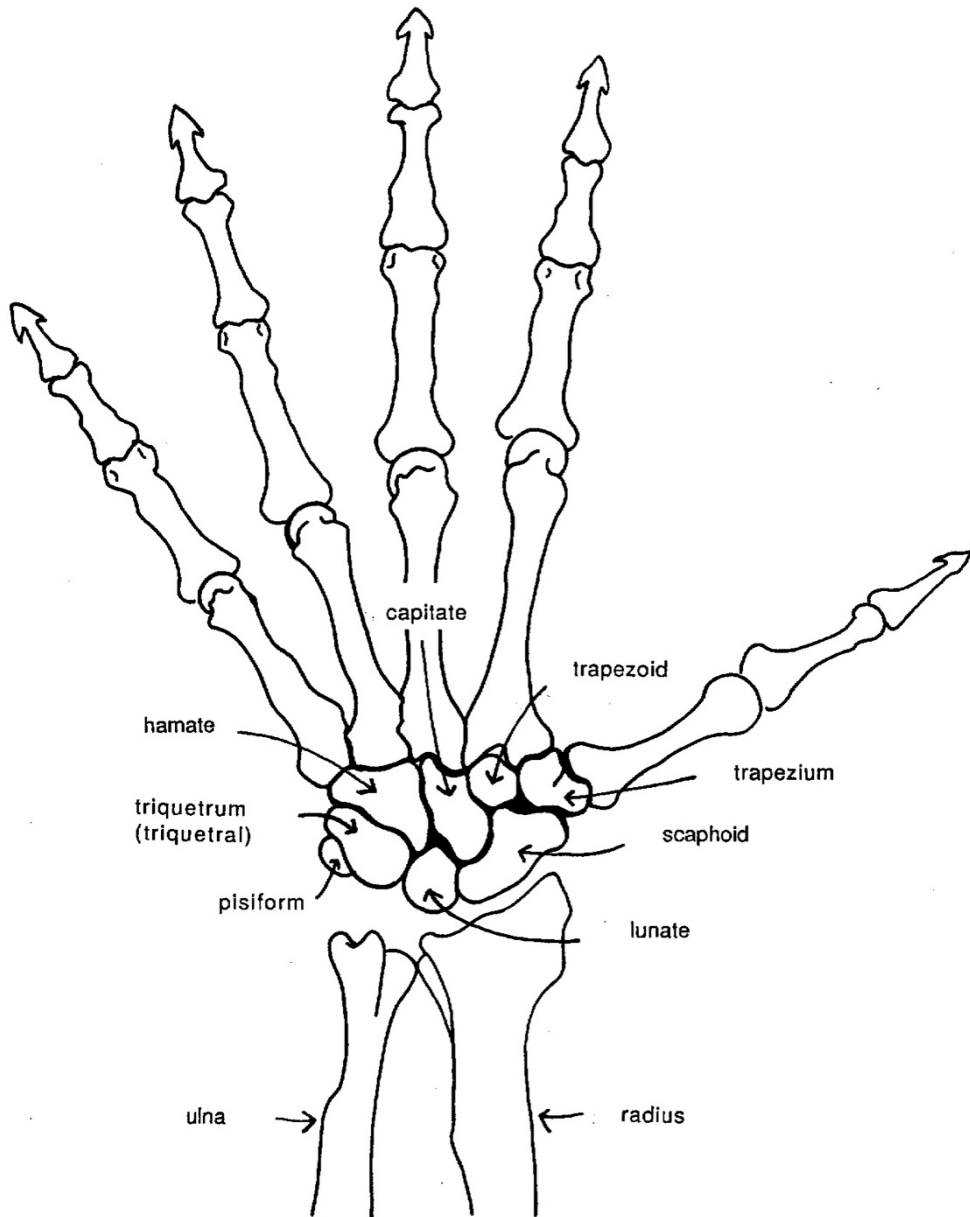
All illustrations drawn freehand by Irene Dowd between 1970 and 2024 drawn from live models, human bone skeleton, cadaver dissection, photographs of moving figures, x-rays and MRI scans, in addition to schematics created by Irene to illustrate various ideas & images



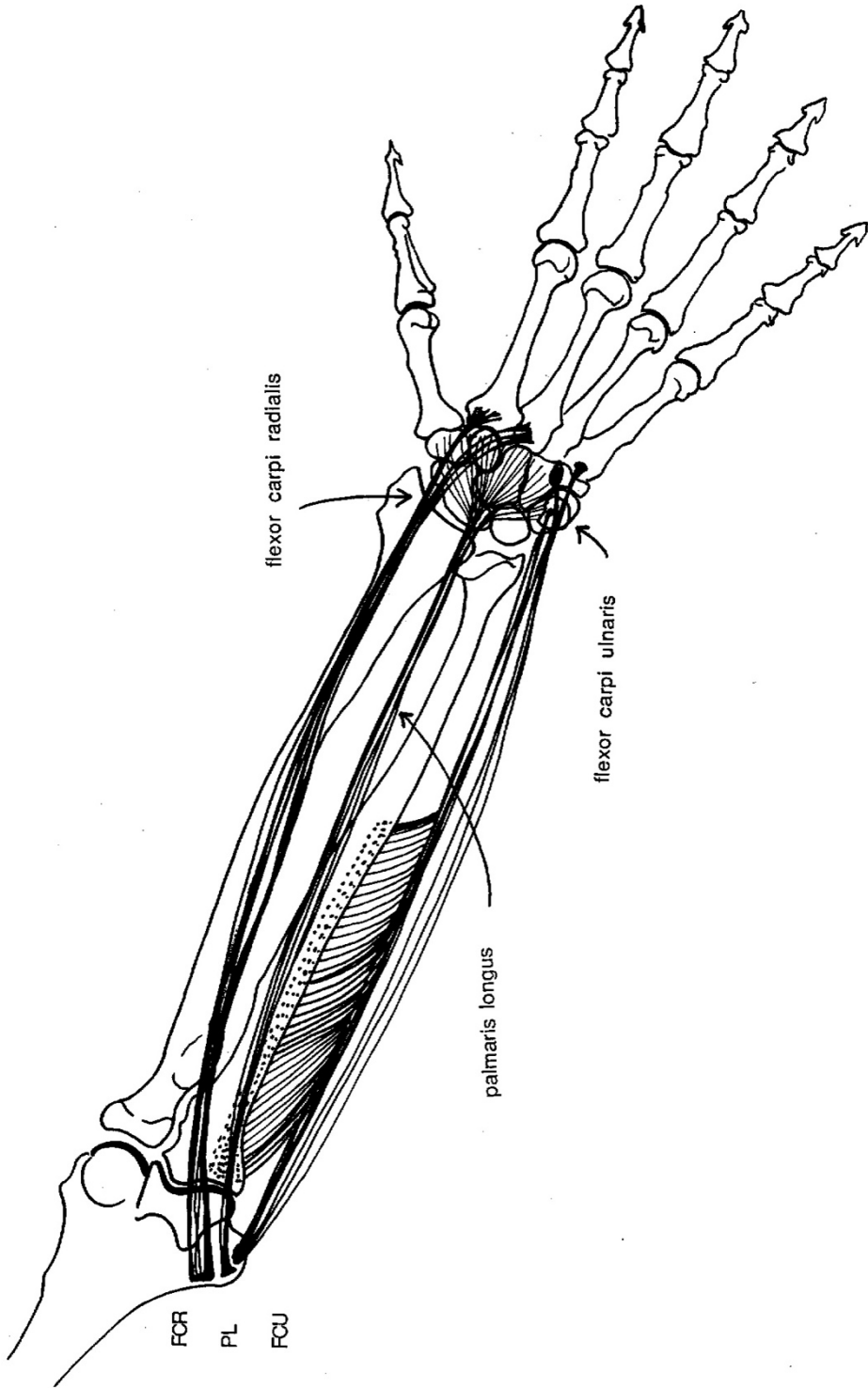
LEFT PALMAR HAND



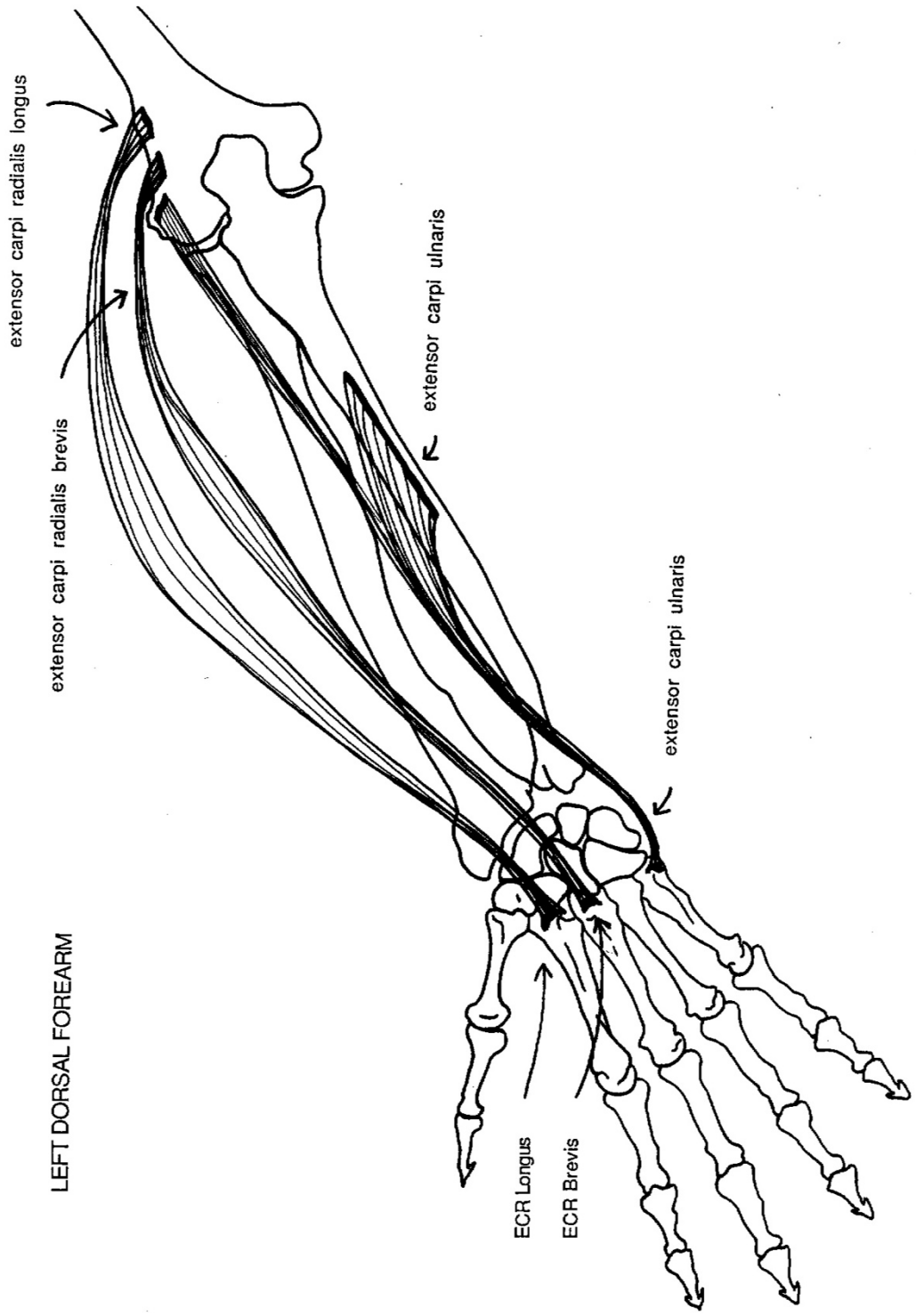
LEFT DORSAL HAND



LEFT PALMAR FOREARM



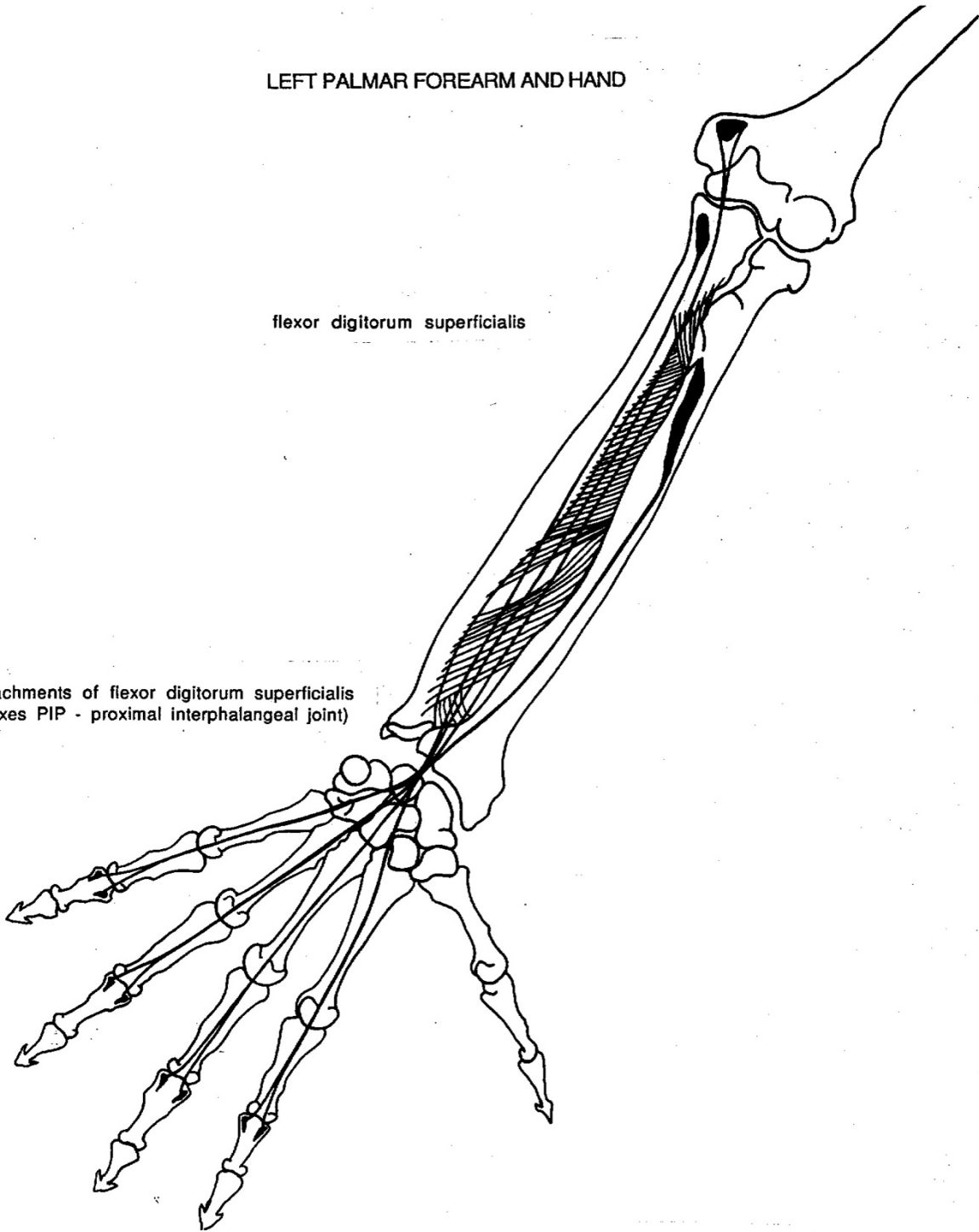
LEFT DORSAL FOREARM



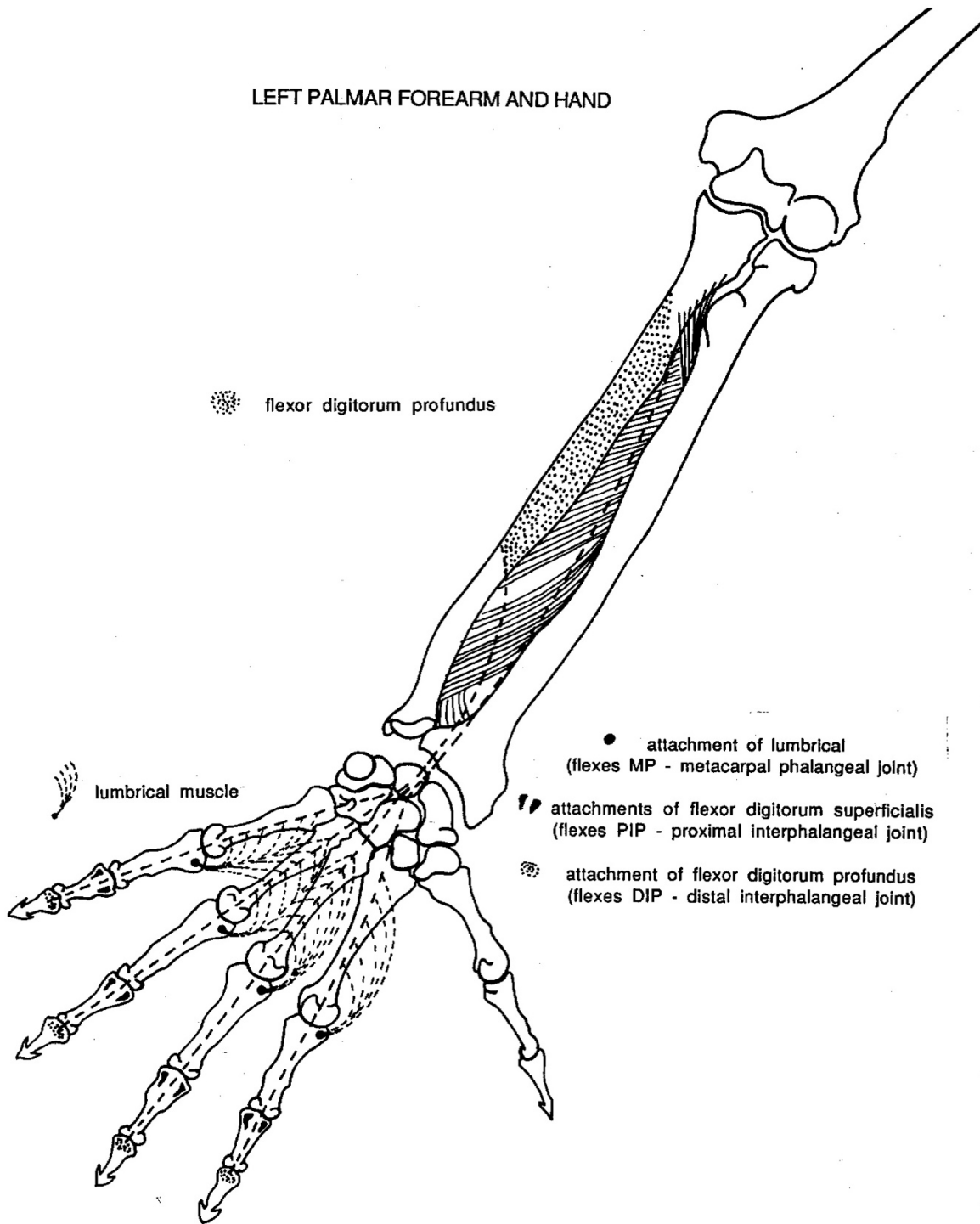
LEFT PALMAR FOREARM AND HAND

flexor digitorum superficialis

attachments of flexor digitorum superficialis  
(flexes PIP - proximal interphalangeal joint)



LEFT PALMAR FOREARM AND HAND



flexor digitorum profundus

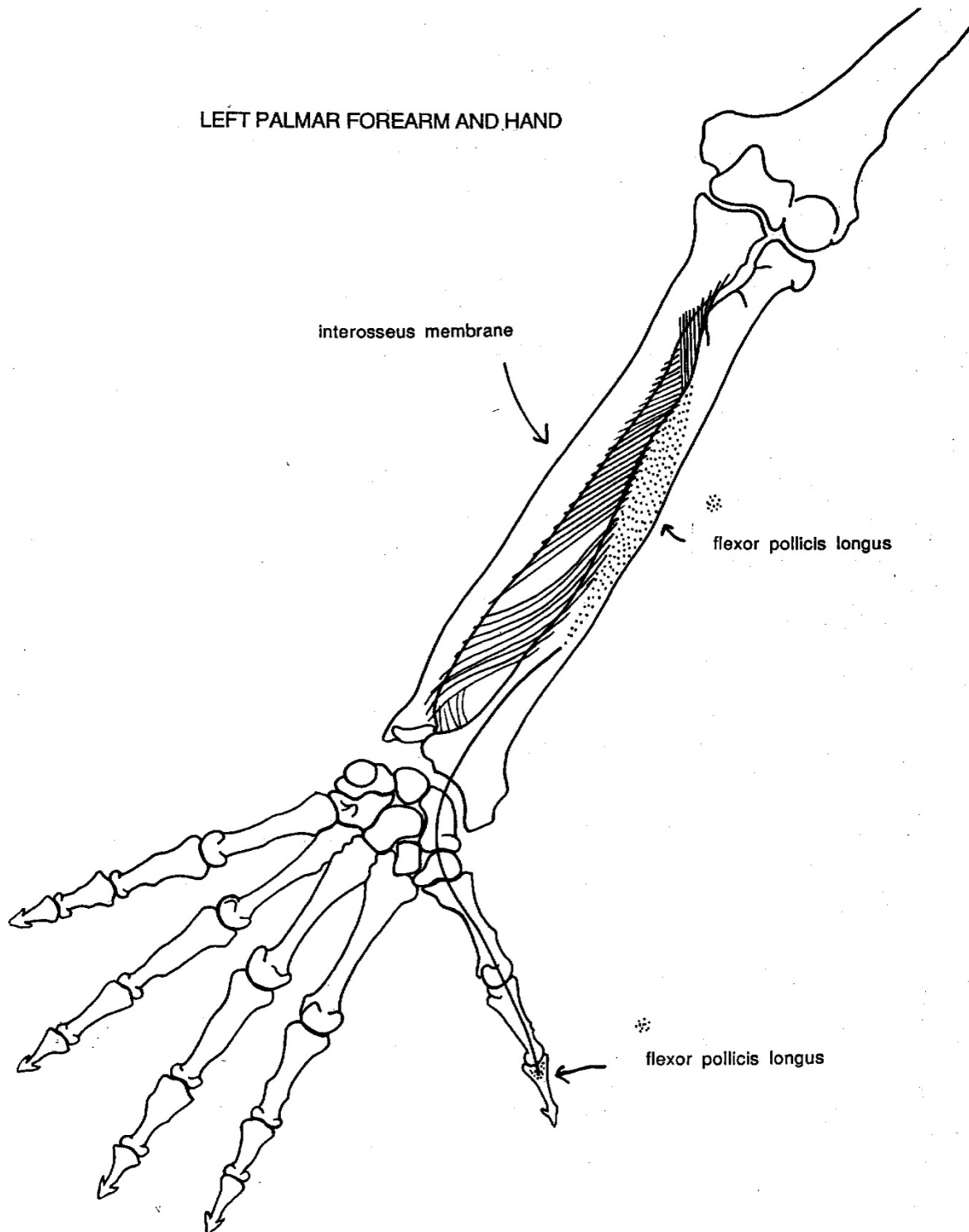
lumbrical muscle

● attachment of lumbrical  
(flexes MP - metacarpal phalangeal joint)

↔ attachments of flexor digitorum superficialis  
(flexes PIP - proximal interphalangeal joint)

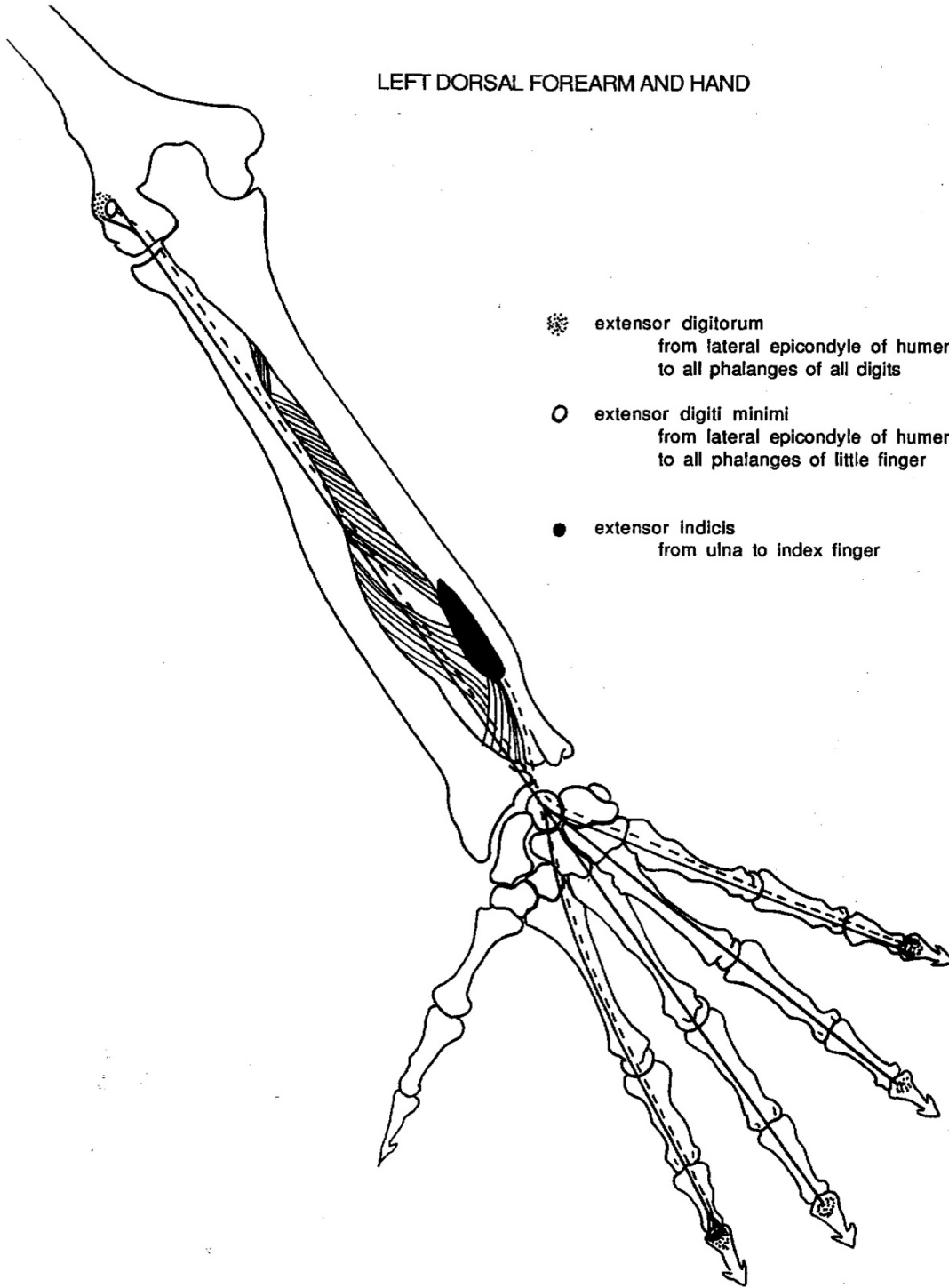
● attachment of flexor digitorum profundus  
(flexes DIP - distal interphalangeal joint)

LEFT PALMAR FOREARM AND HAND





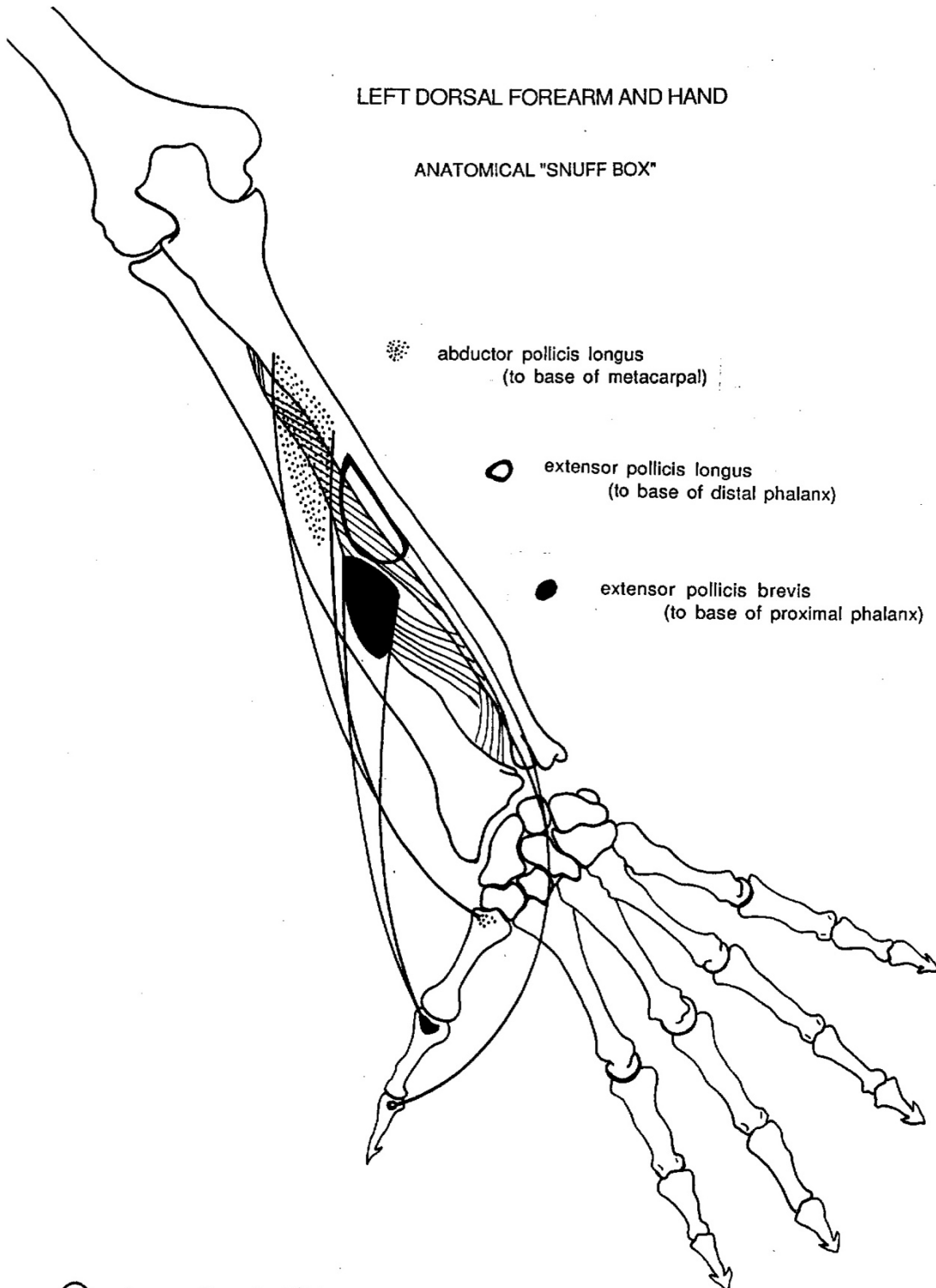
LEFT DORSAL FOREARM AND HAND



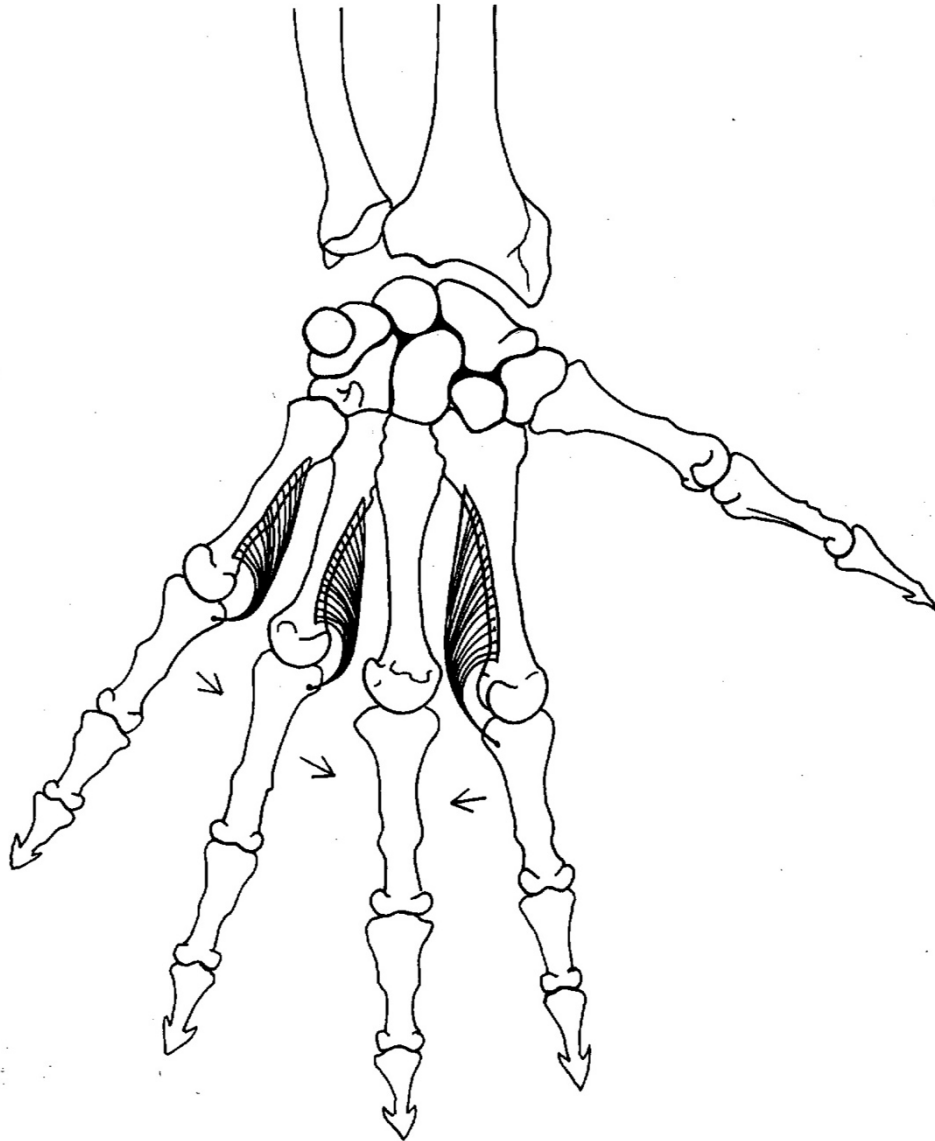
- ☼ extensor digitorum  
from lateral epicondyle of humerus  
to all phalanges of all digits
- extensor digiti minimi  
from lateral epicondyle of humerus  
to all phalanges of little finger
- extensor indicis  
from ulna to index finger

LEFT DORSAL FOREARM AND HAND

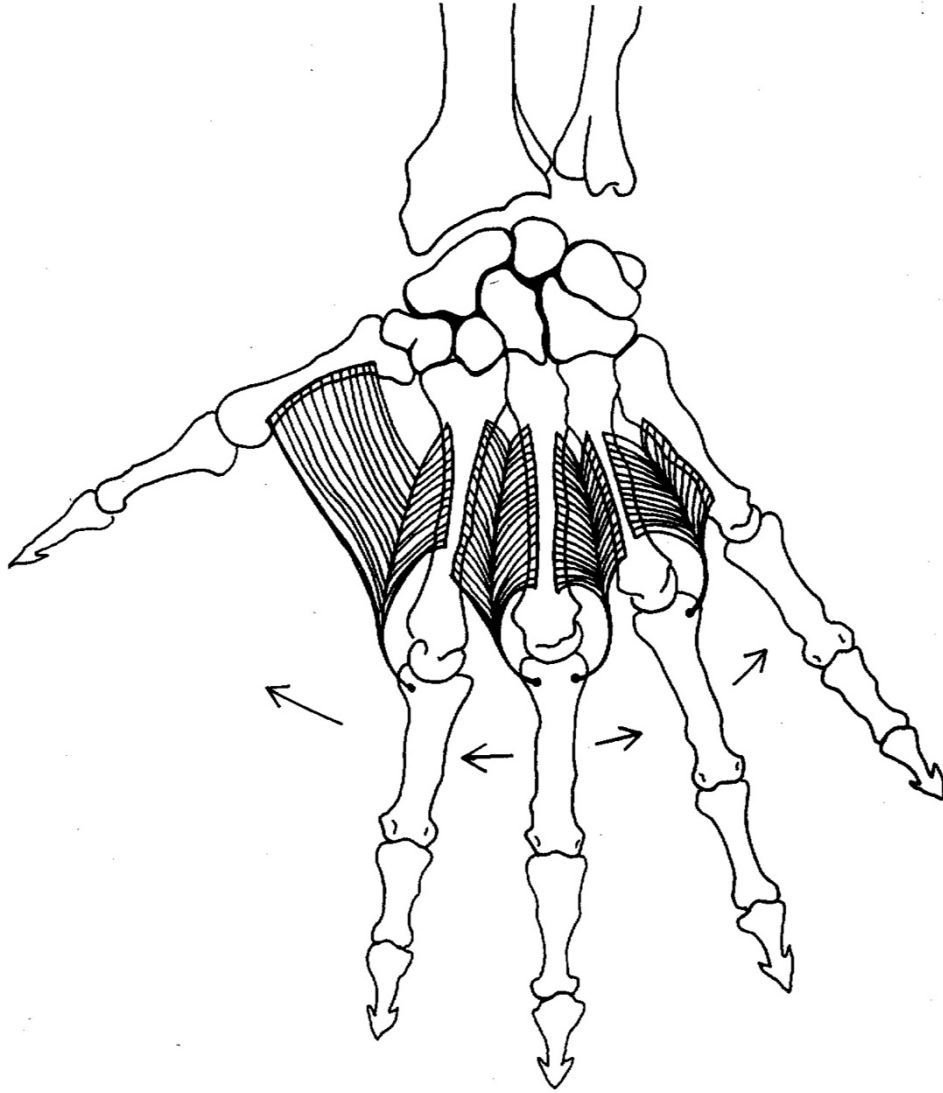
ANATOMICAL "SNUFF BOX"



LEFT PALMAR HAND: INTEROSSEI MUSCLES  
(adduct toward middle finger)



LEFT DORSAL HAND: INTEROSSEI MUSCLES  
(abduct from midline of hand,  
thus middle finger moves away to either side)



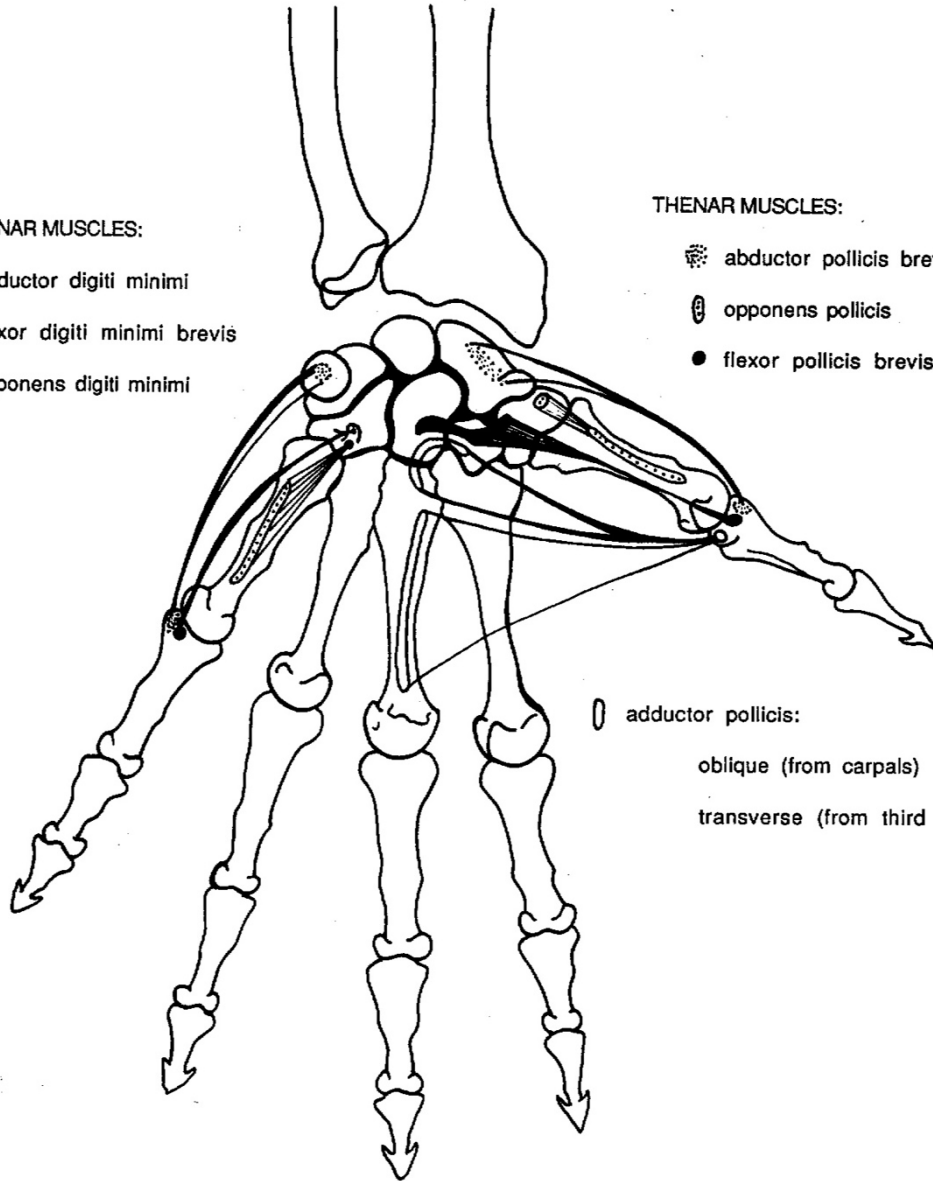
LEFT PALMAR HAND

HYPOTHENAR MUSCLES:

- abductor digiti minimi
- flexor digiti minimi brevis
- opponens digiti minimi

THENAR MUSCLES:

- abductor pollicis brevis
- opponens pollicis
- flexor pollicis brevis



- adductor pollicis:
  - oblique (from carpals)
  - transverse (from third metacarpal)