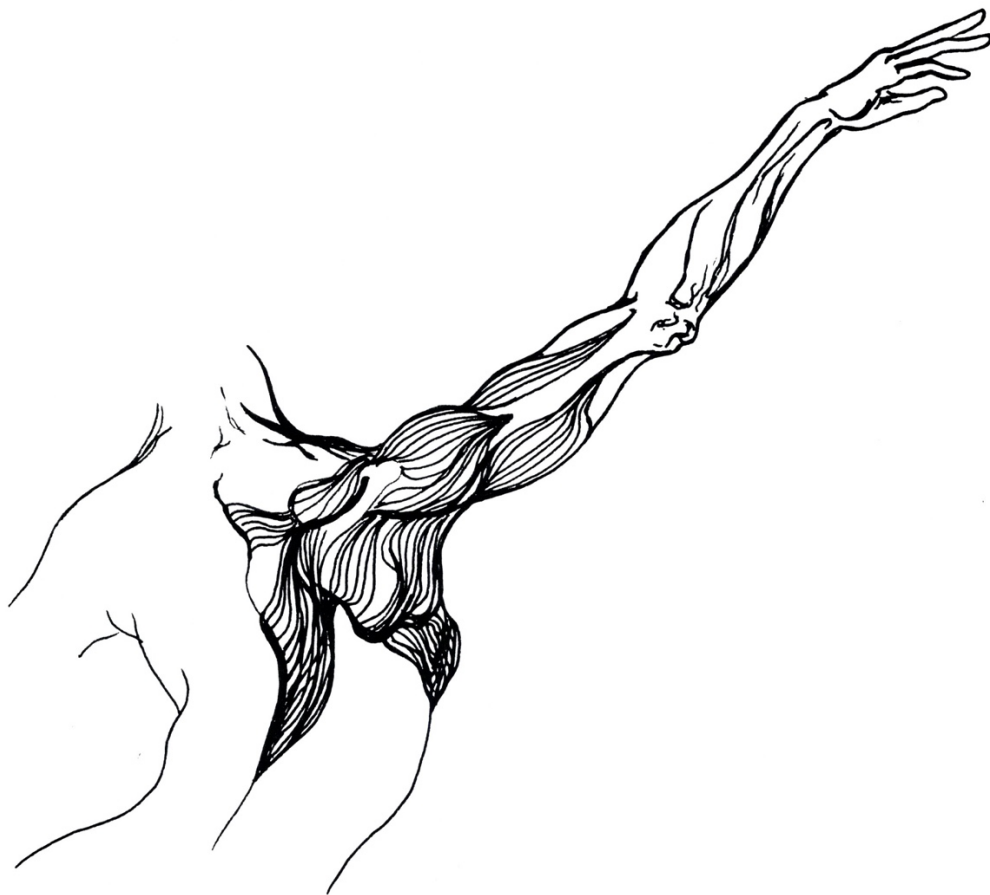
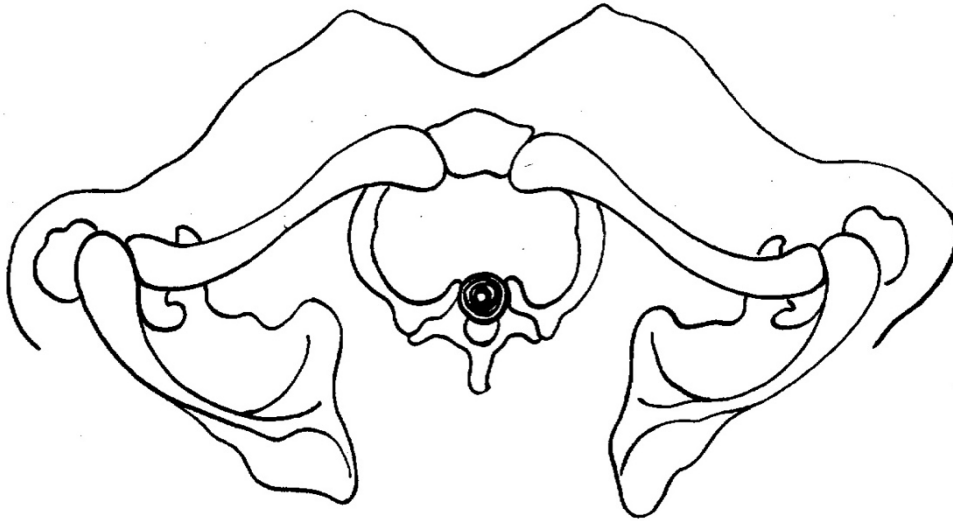


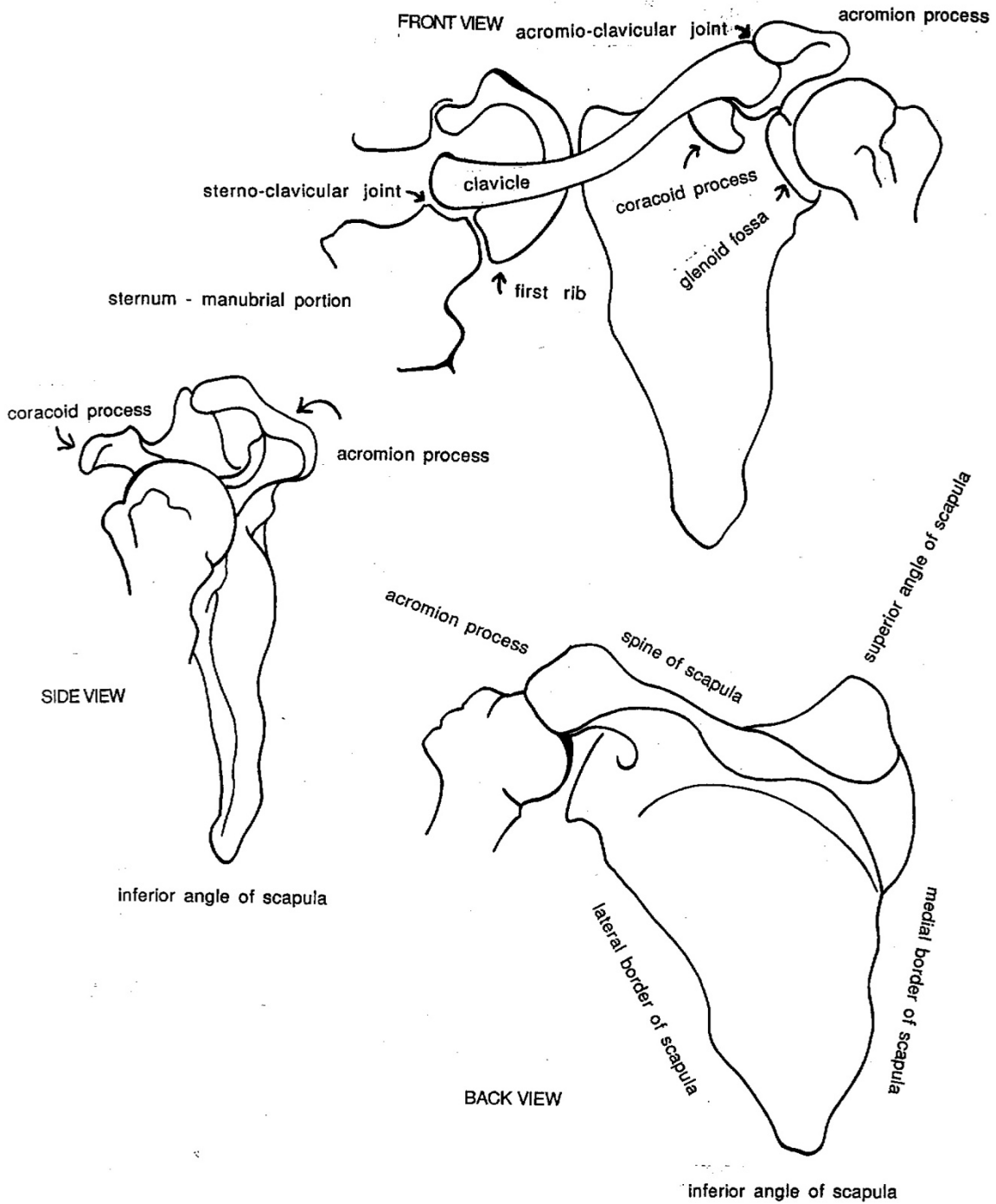
## **ILLUSTRATIONS OF THE SHOULDER GIRDLE - BONES, MOVEMENT AND MUSCLES**

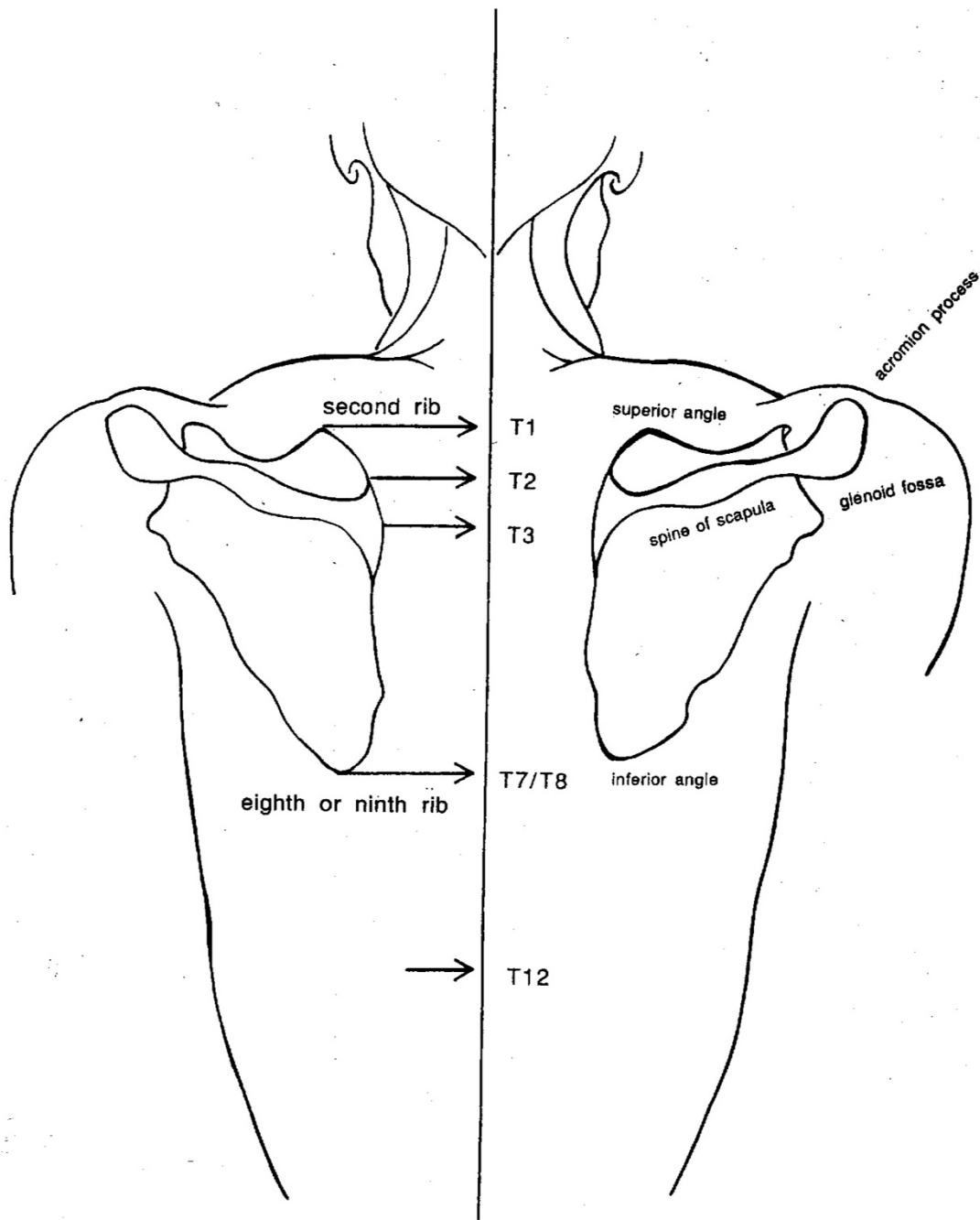
All illustrations drawn freehand by Irene Dowd between 1970 and 2024 drawn from live models, human bone skeleton, cadaver dissection, photographs of moving figures, x-rays and MRI scans, in addition to schematics created by Irene to illustrate various ideas & images



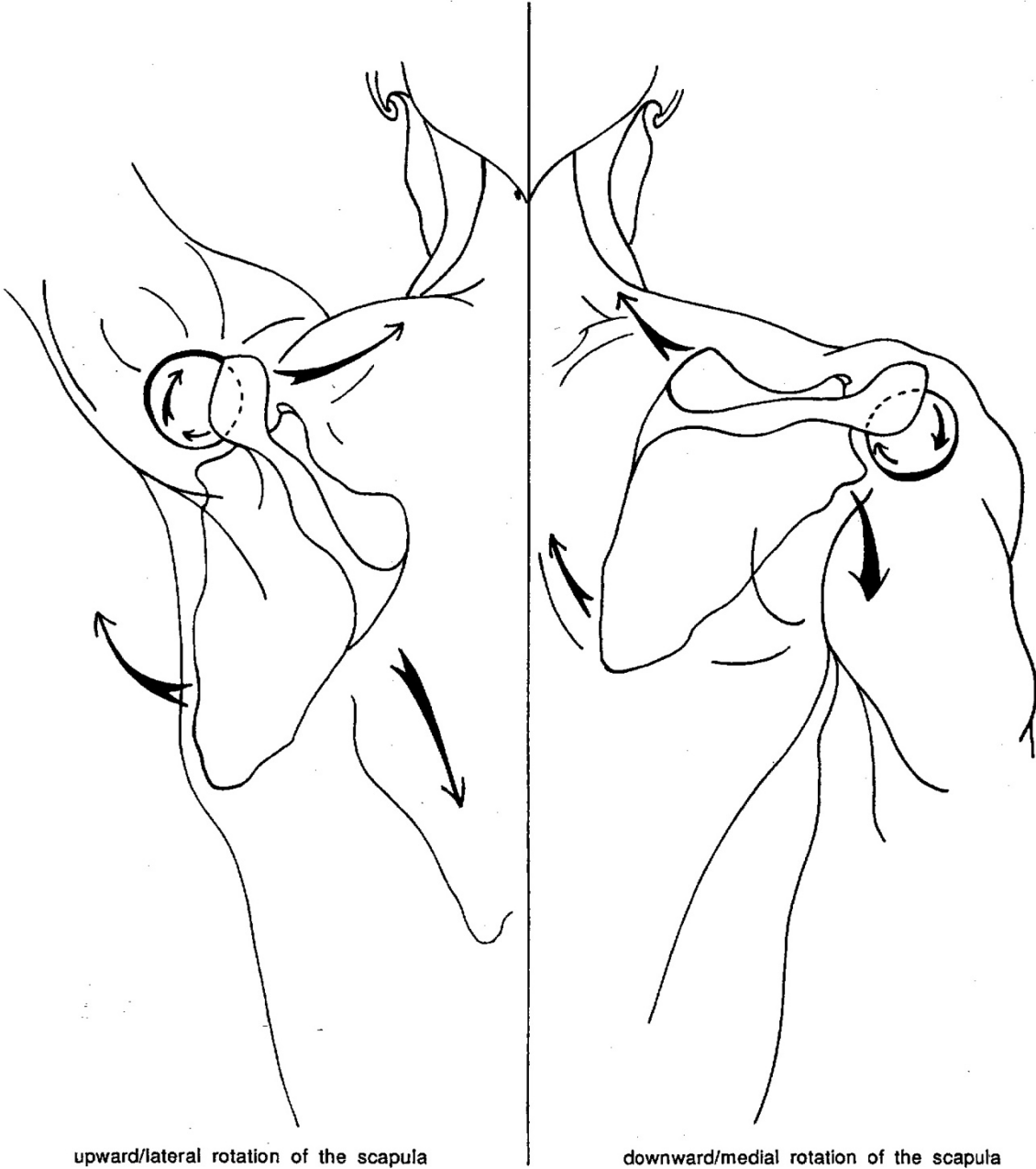
VIEW OF SHOULDER GIRDLE FROM ABOVE





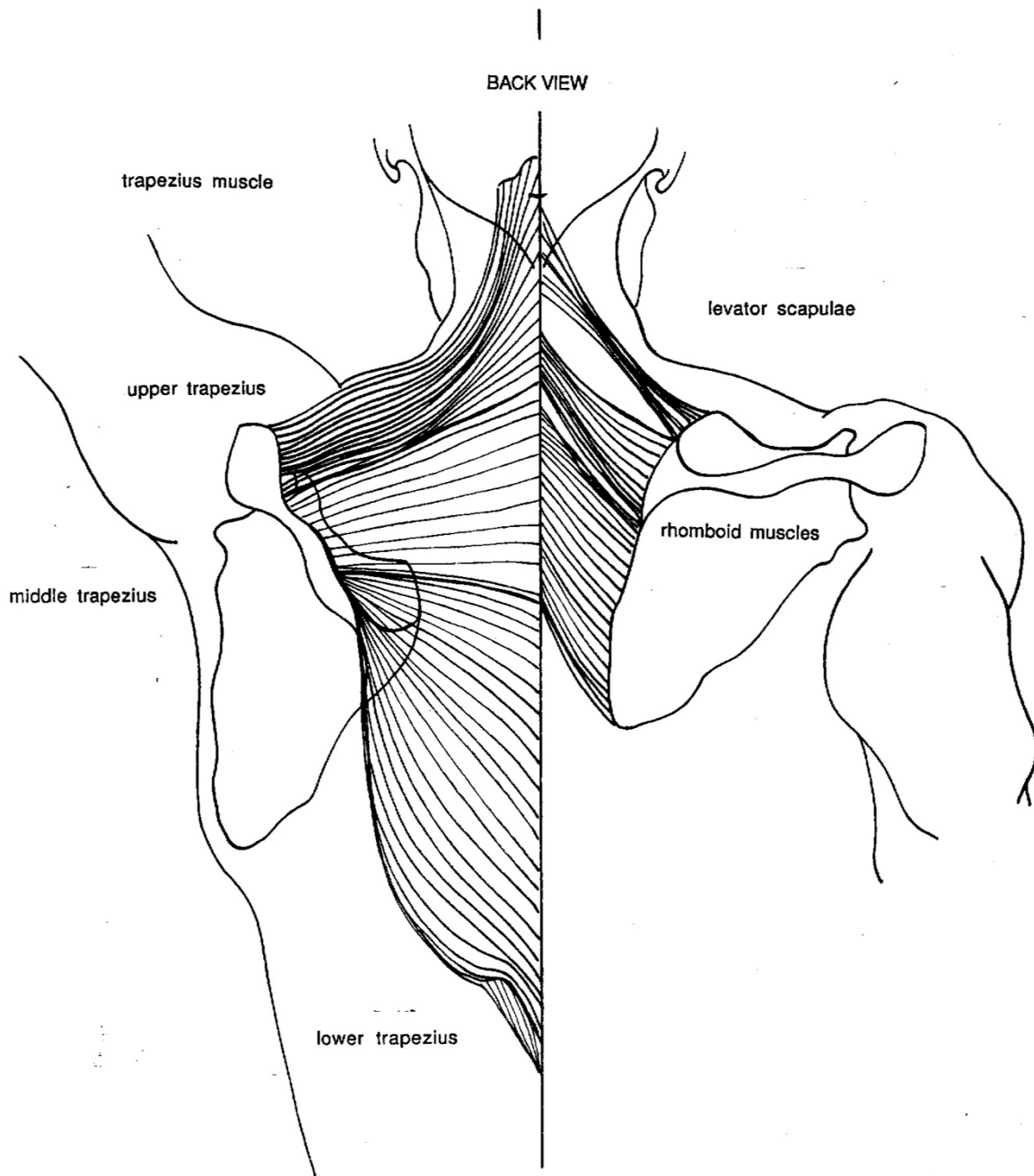


BACK VIEW

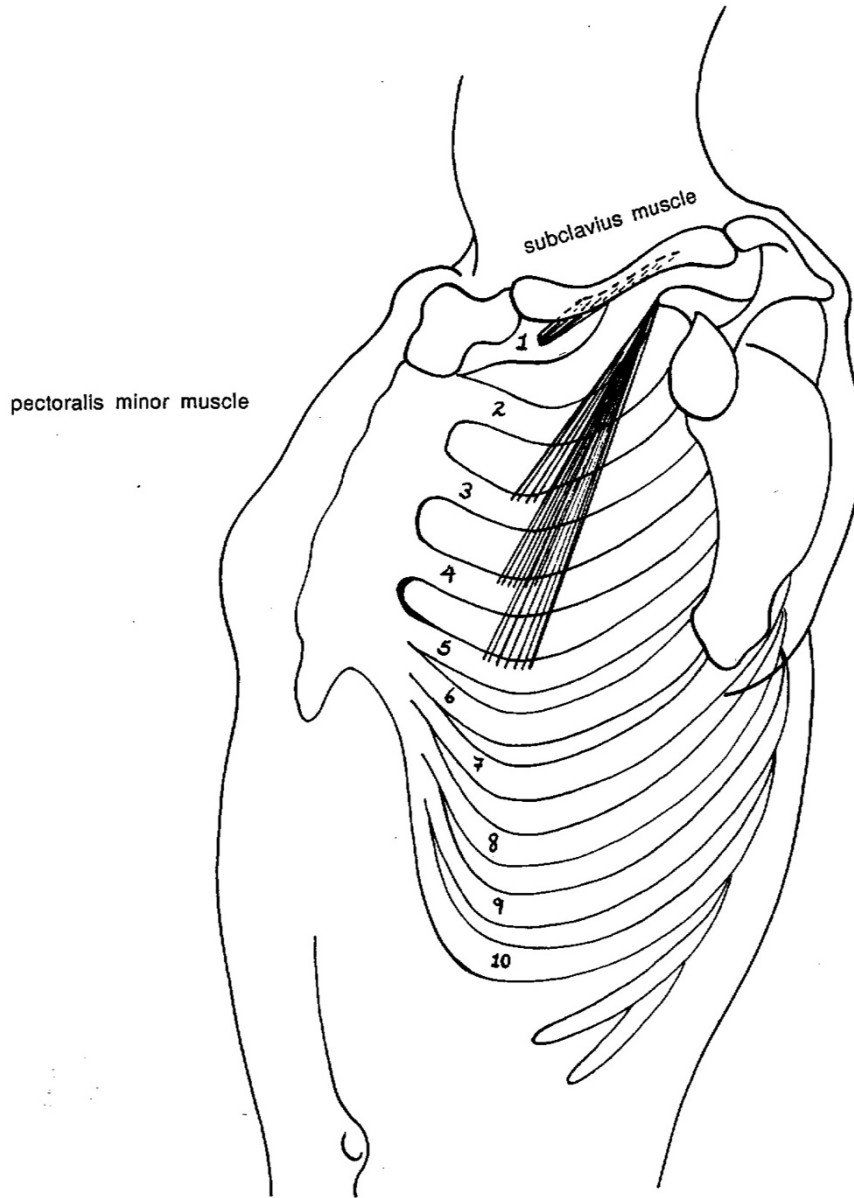


upward/lateral rotation of the scapula

downward/medial rotation of the scapula



SIDE/FRONT VIEW

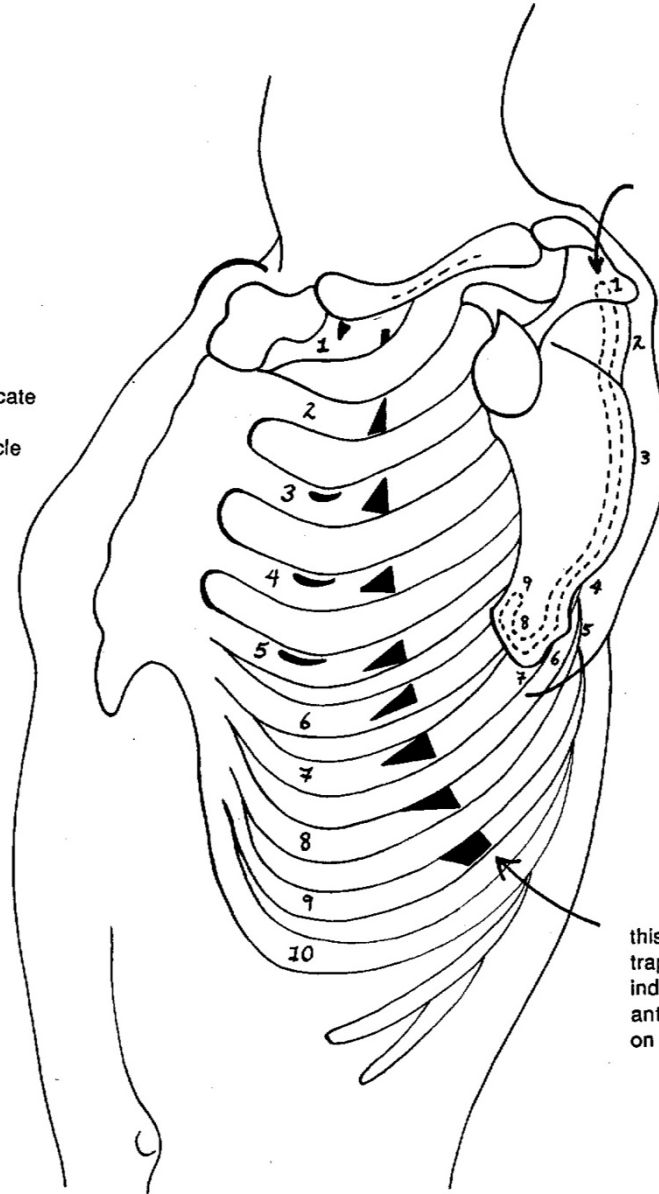


pectoralis minor muscle

subclavius muscle

SIDE/FRONT VIEW

half-moon marks indicate  
attachments of  
pectoralis minor muscle



dotted line marking -  
on surface of scapula  
which is in contact  
with ribs - indicates  
attachments of various  
segments of  
anterior serratus  
from the rib cage

this curving line of  
trapezoid and triangle marks  
indicate attachments of  
anterior serratus muscle  
on the rib cage



SIDE/FRONT VIEW - ANTERIOR SERRATUS MUSCLE

