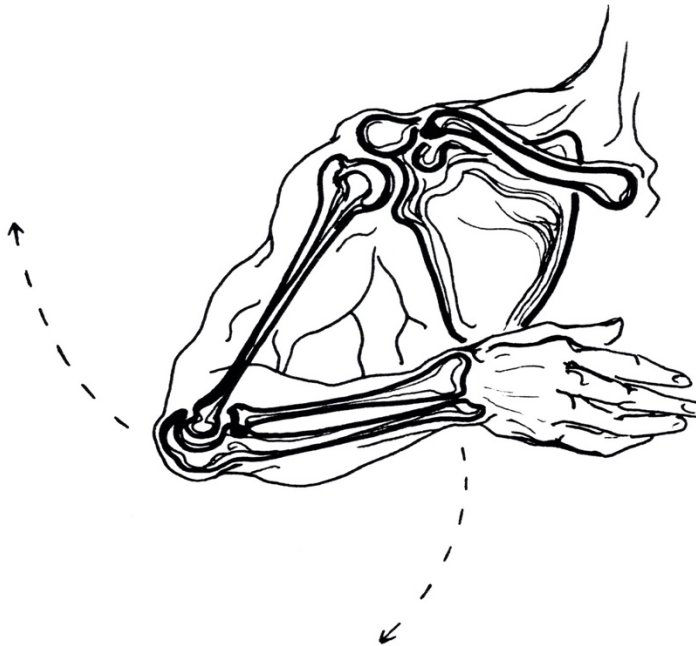


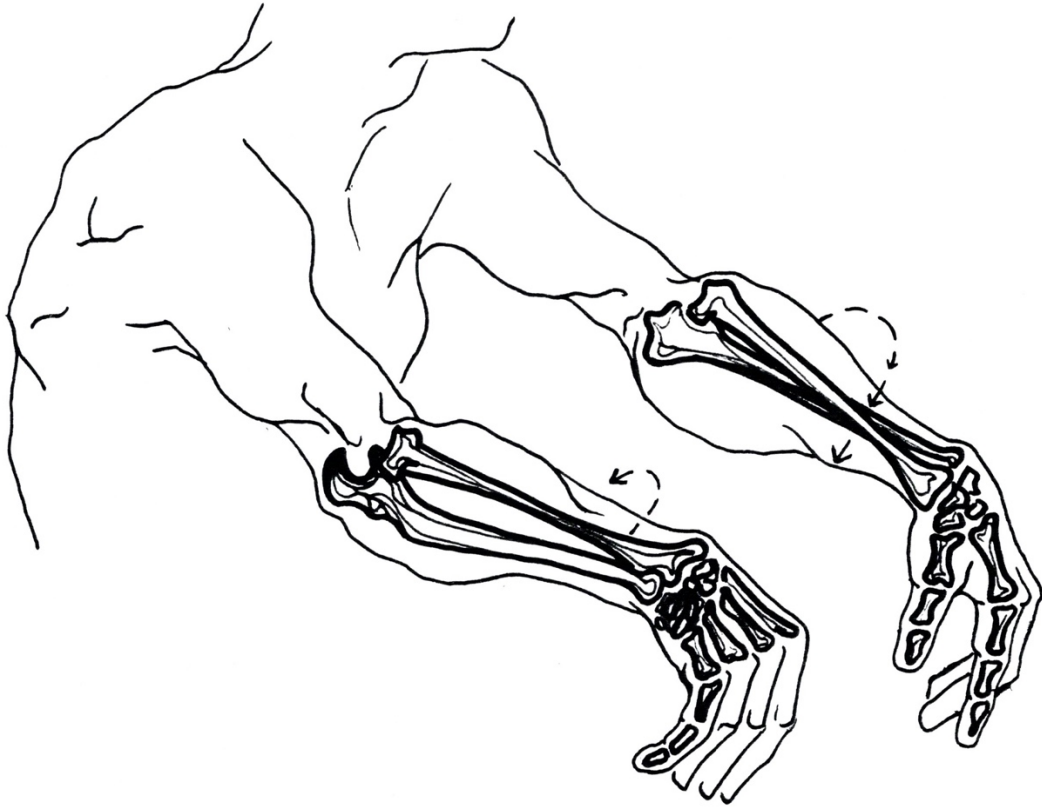
ILLUSTRATIONS OF THE ELBOW AND FOREARM - BONES, MOVEMENT AND MUSCLES

All illustrations drawn freehand by Irene Dowd between 1970 and 2024 drawn from live models, human bone skeleton, cadaver dissection, photographs of moving figures, x-rays and MRI scans, in addition to schematics created by Irene to illustrate various ideas & images

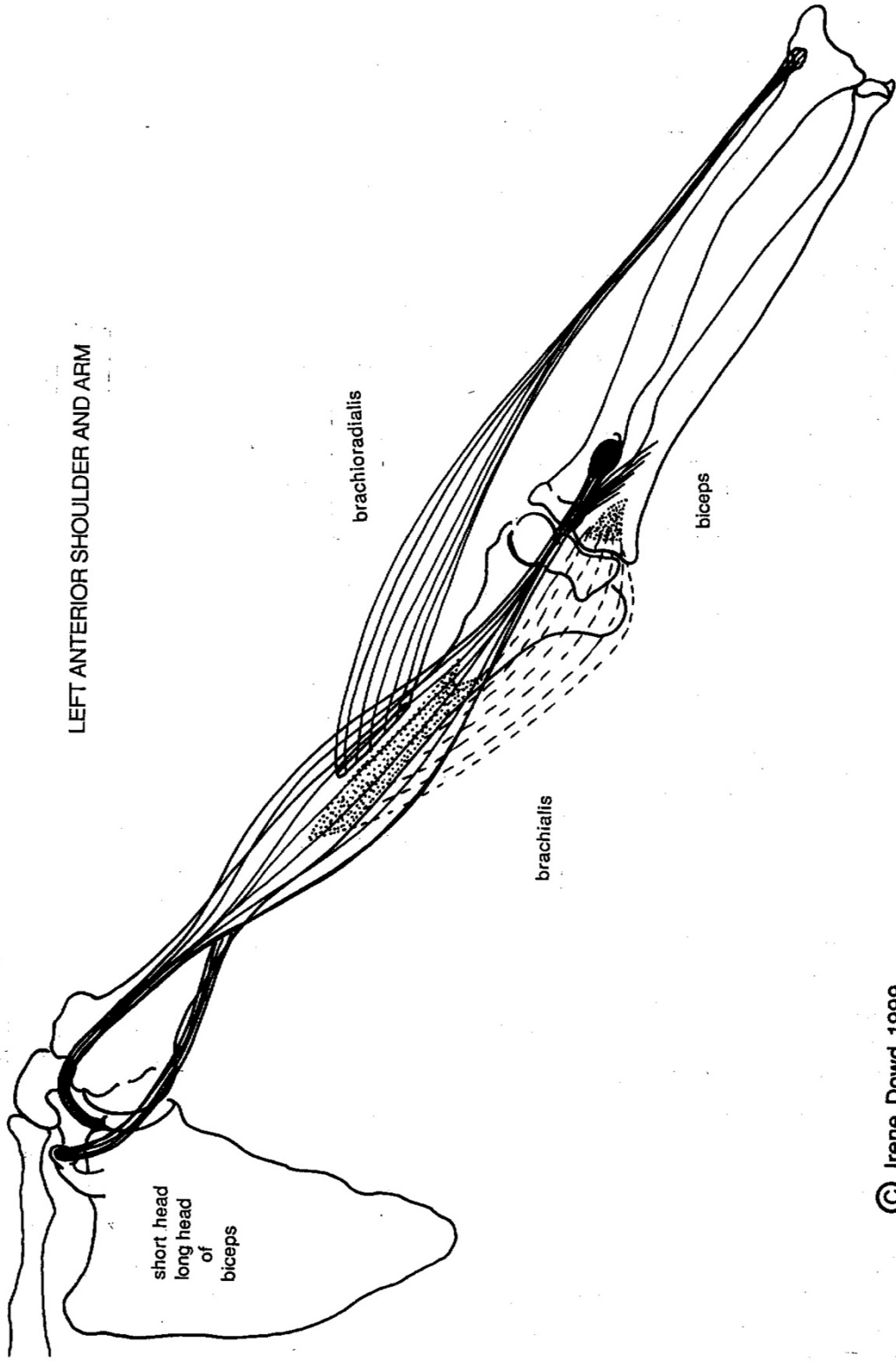
elbow motion, and bones that form elbow joint



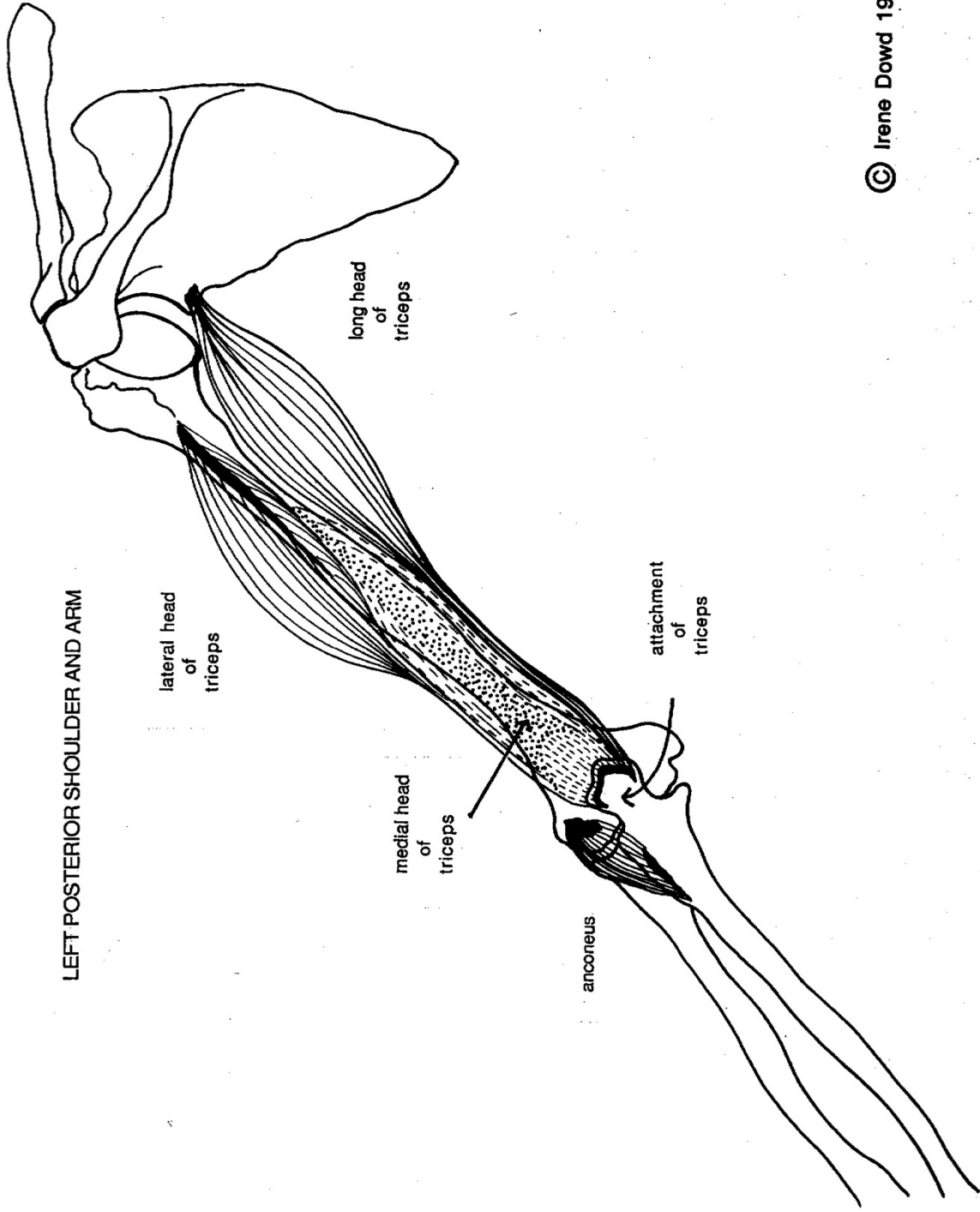
forearm motion



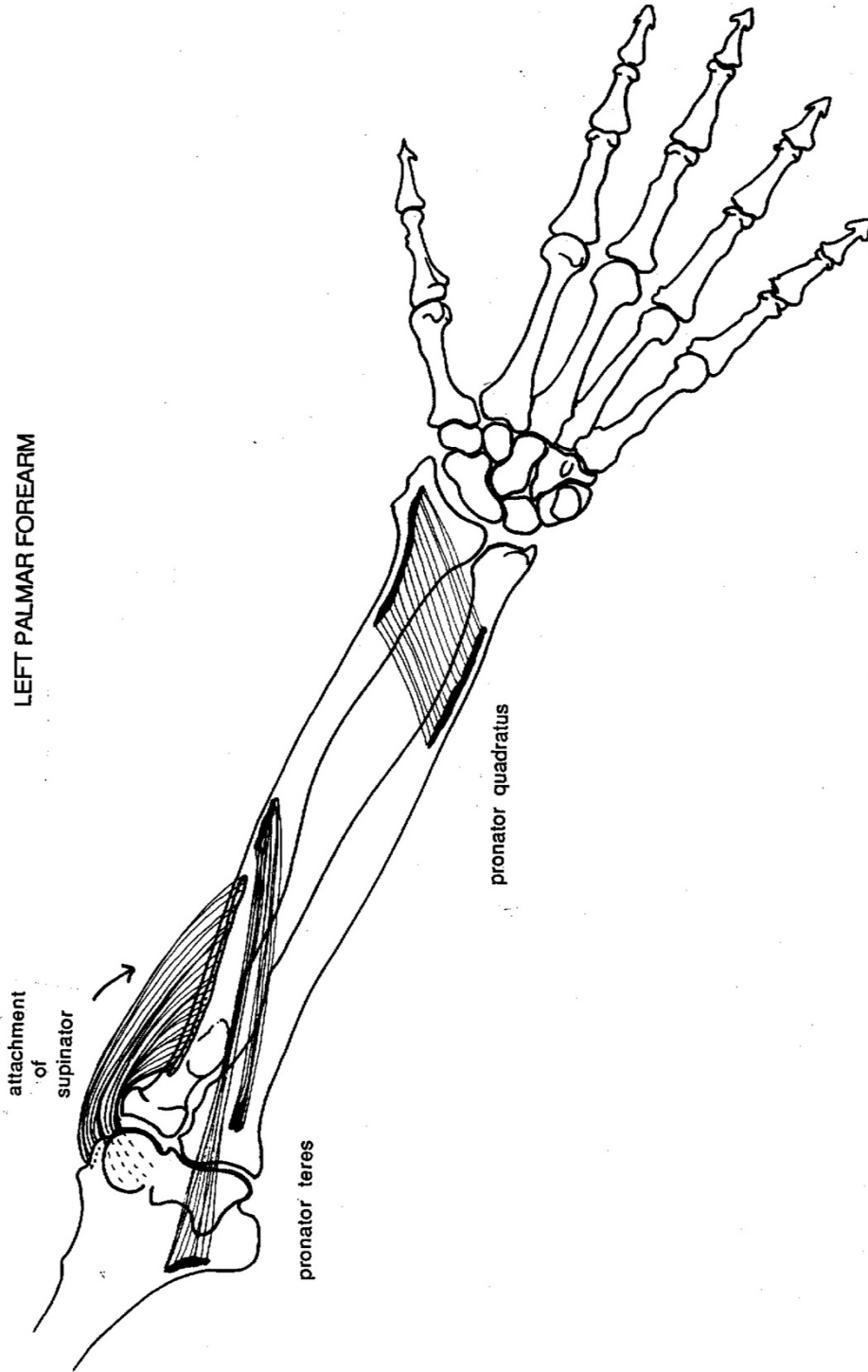
LEFT ANTERIOR SHOULDER AND ARM



LEFT POSTERIOR SHOULDER AND ARM



LEFT PALMAR FOREARM



LEFT DORSAL FOREARM

