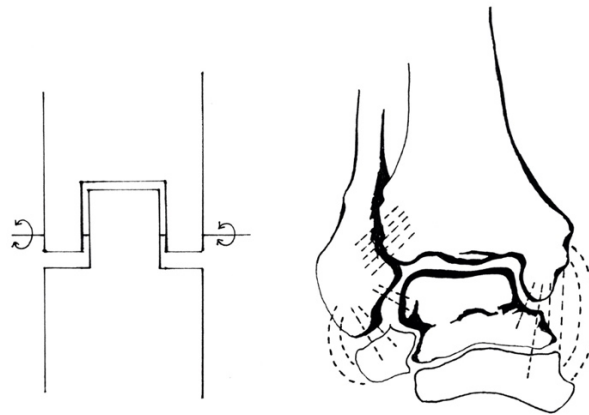
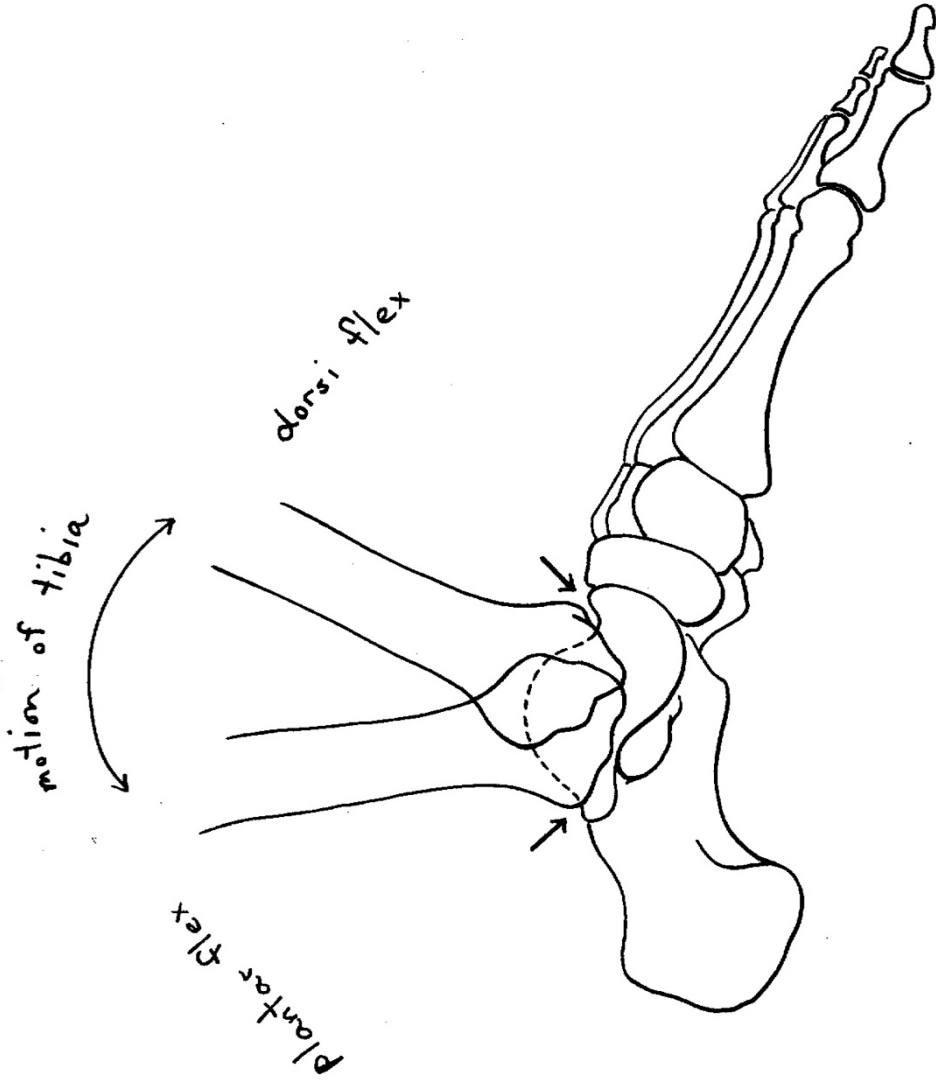


## ILLUSTRATIONS OF THE ANKLE - BONES, JOINTS, MUSCLES, MOVEMENT

All illustrations drawn freehand by Irene Dowd between 1970 and 2024

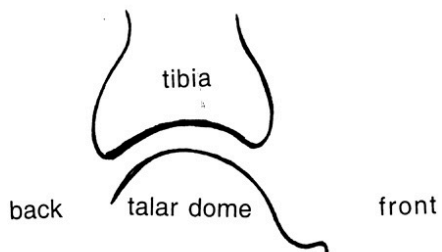
drawn from live models, human bone skeleton, cadaver dissection, photographs of moving figures, x-rays and MRI scans, in addition to schematics created by Irene to illustrate various ideas & images



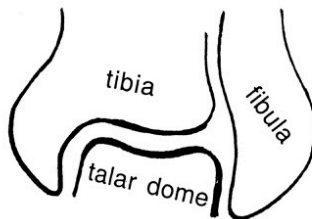


**ANKLE JOINT (TALO-CRURAL JOINT)**

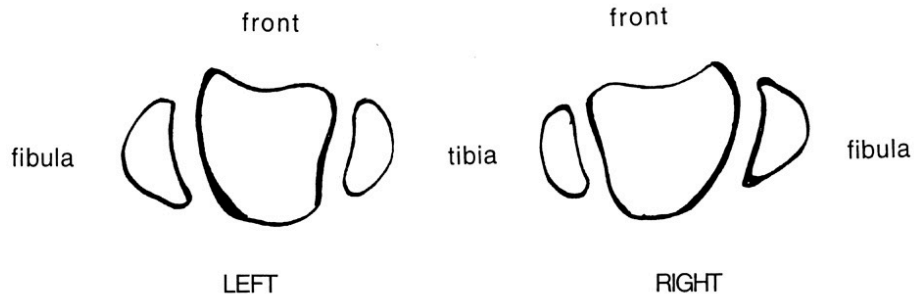
**SIDE VIEW**  
(cut through  
median sagittal  
plane of one  
ankle joint)



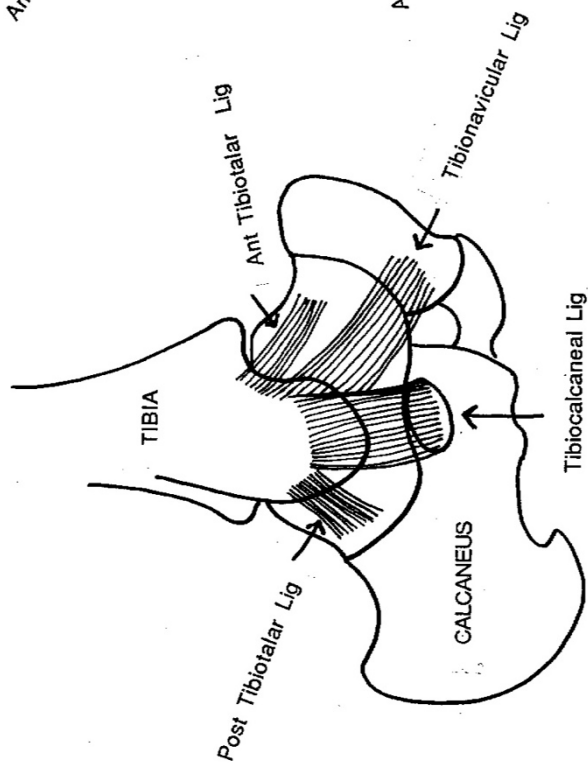
**BACK/FRONT VIEW**  
(frontal/transverse  
plane of one  
ankle joint)



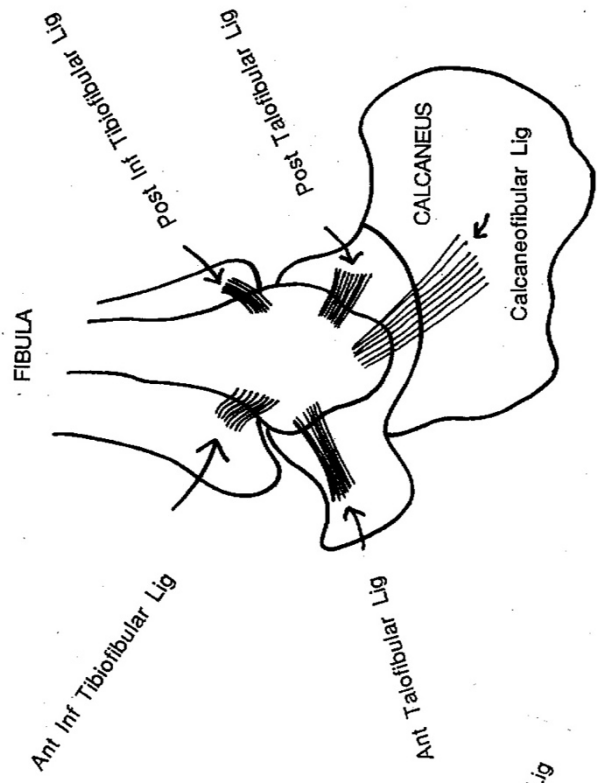
**VIEW FROM ABOVE**  
(horizontal cut showing  
top of talar dome)



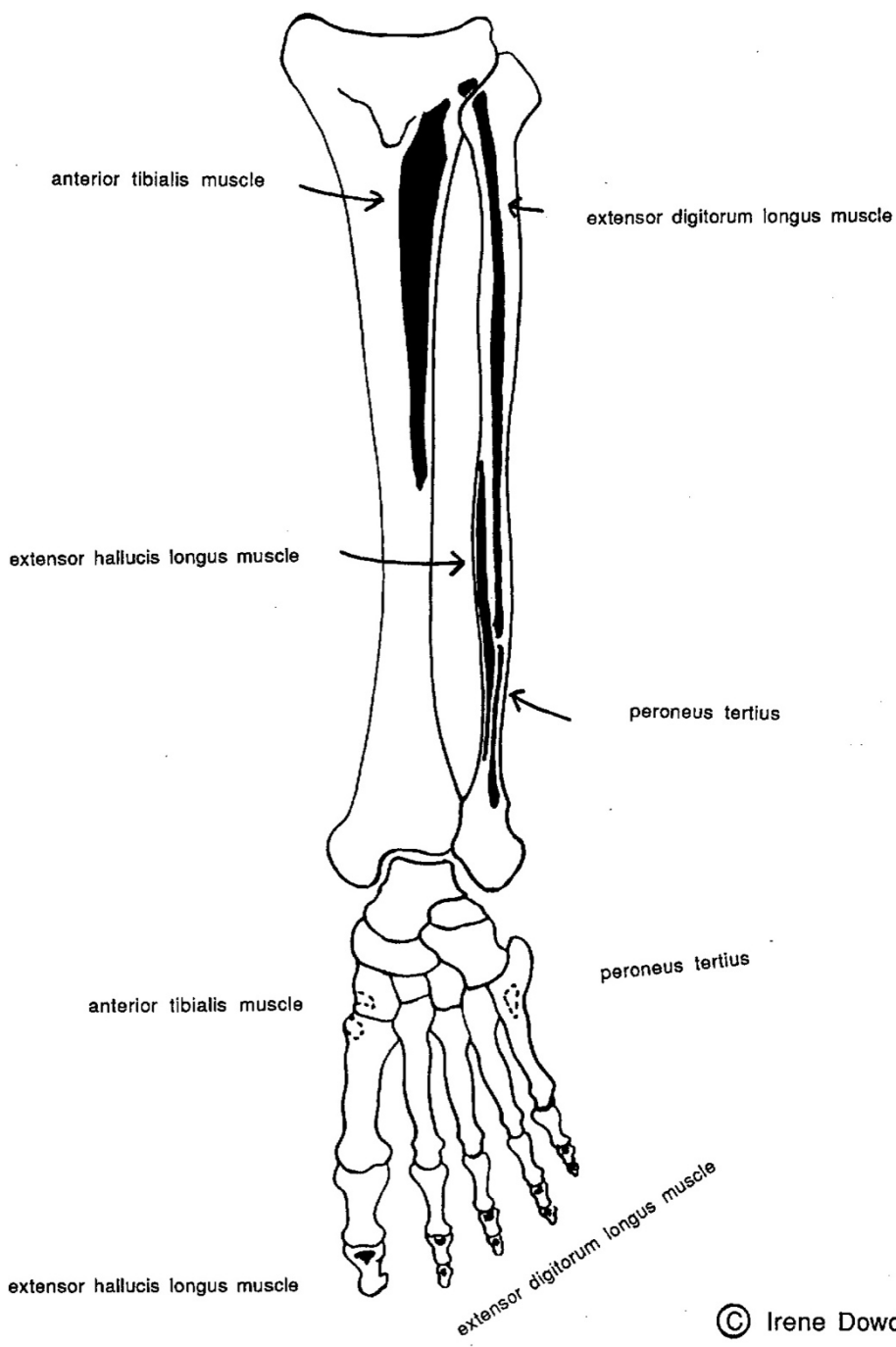
**Medial Ankle:**  
Deltoid Ligament



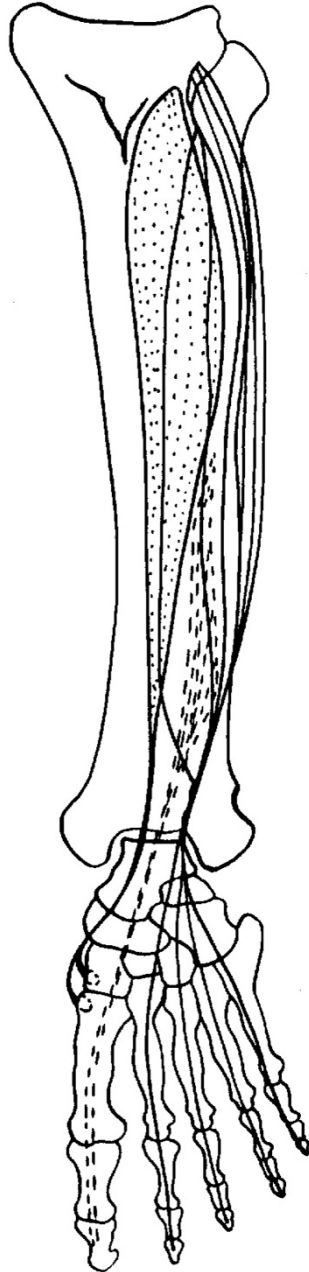
**Lateral Ankle**



ANTERIOR LEG



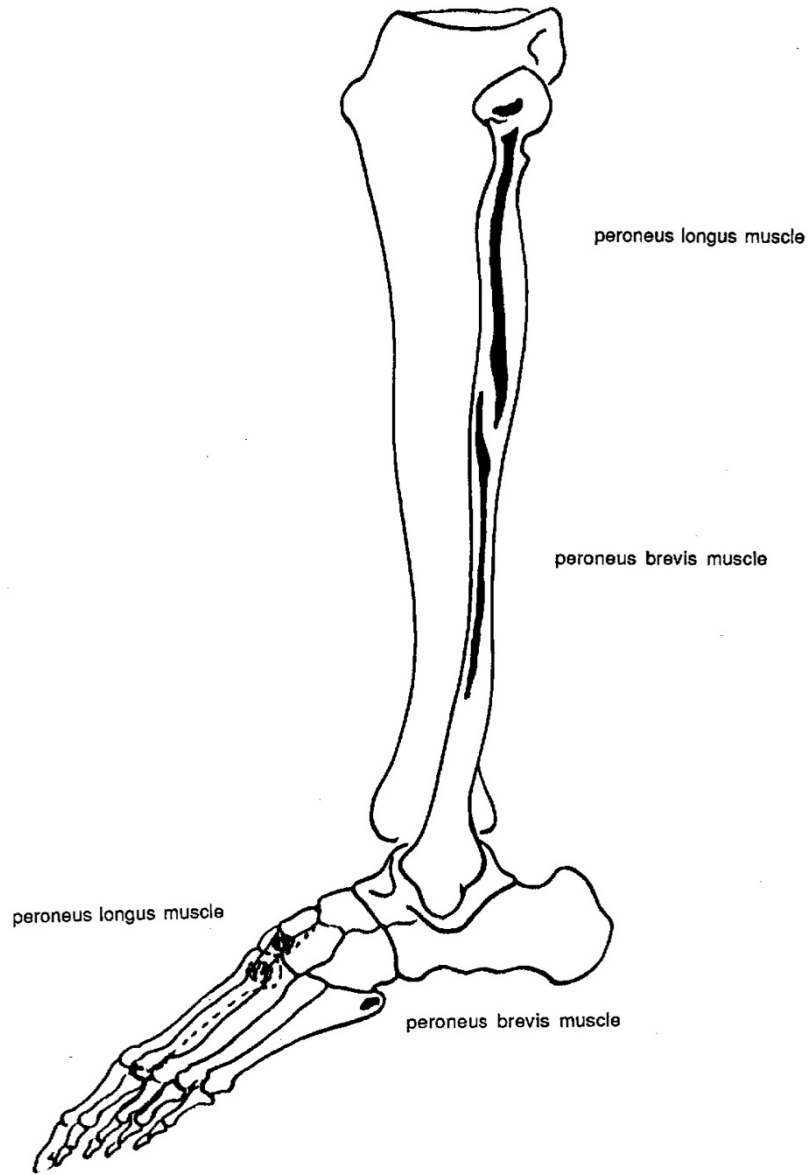
ANTERIOR LEG



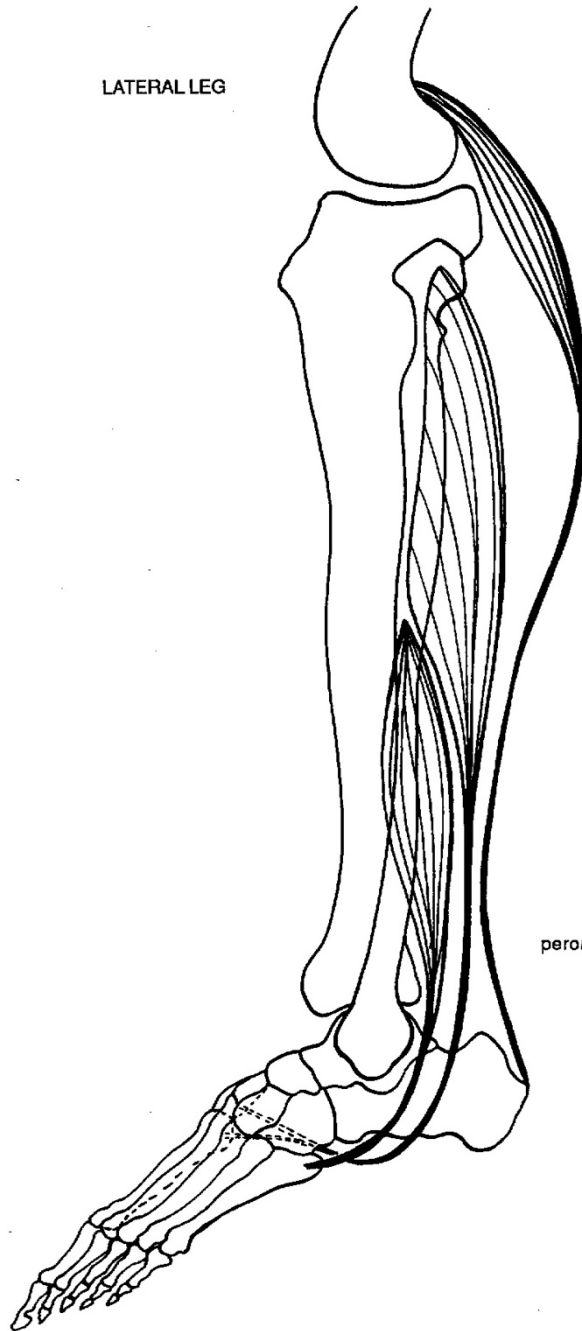
tendons from medial  
to lateral side of ankle:

anterior tibialis muscle  
extensor hallucis longus muscle  
extensor digitorum longus muscle

LATERAL LEG



LATERAL LEG



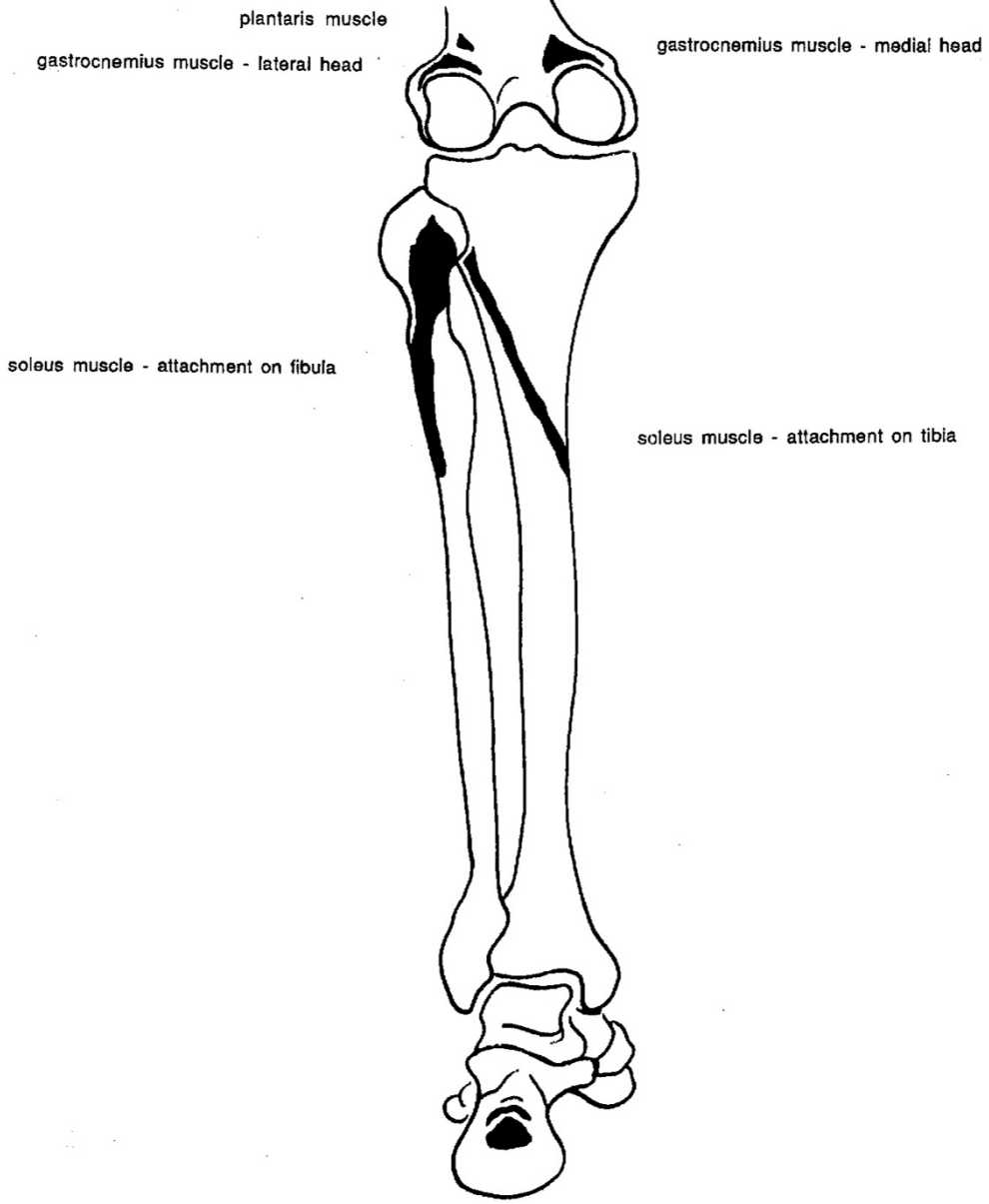
gastrocnemius muscle

peroneus longus muscle

peroneus brevis muscle



POSTERIOR LEG - SUPERFICIAL COMPARTMENT



plantaris muscle  
gastrocnemius muscle - lateral head

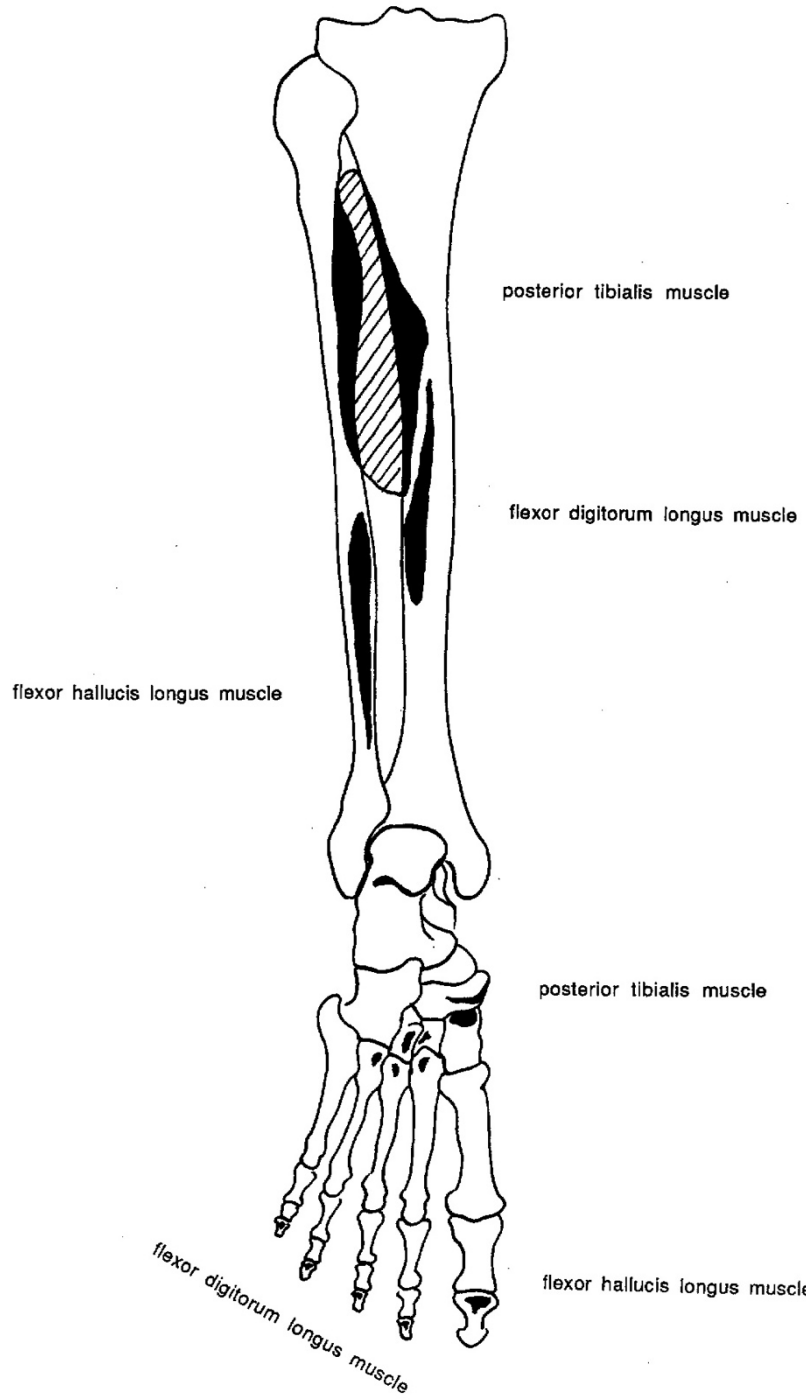
gastrocnemius muscle - medial head

soleus muscle - attachment on fibula

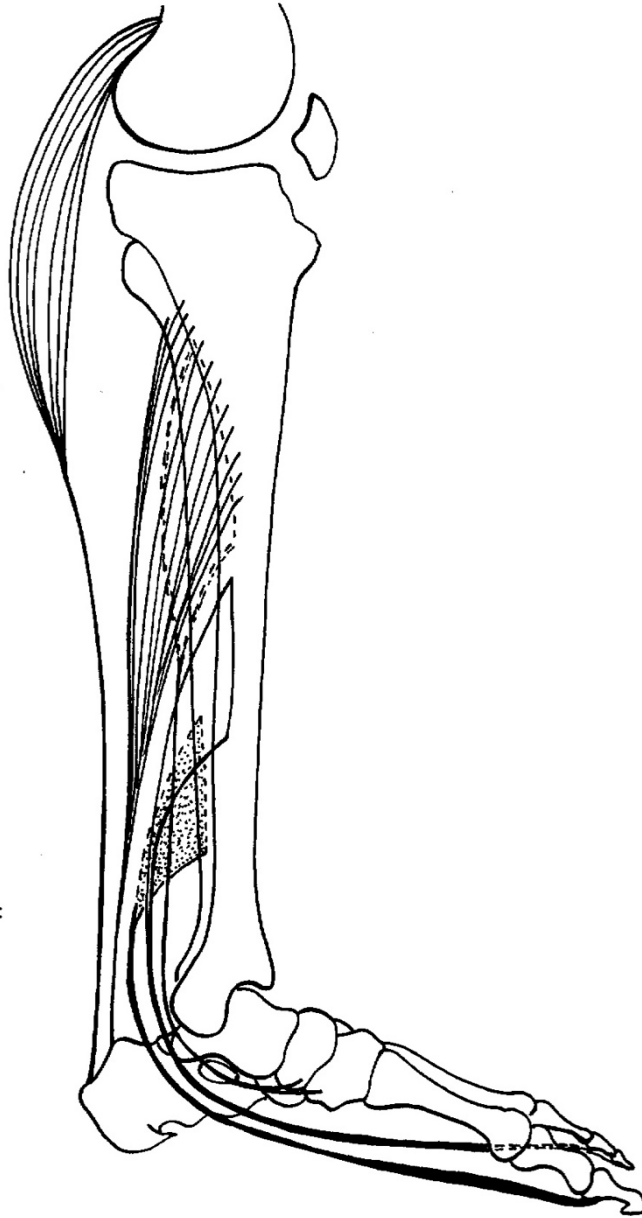soleus muscle - attachment on tibia

achilles tendon:  
soleus attachment  
gastrocnemius & plantaris attachment

POSTERIOR LEG - DEEP COMPARTMENT



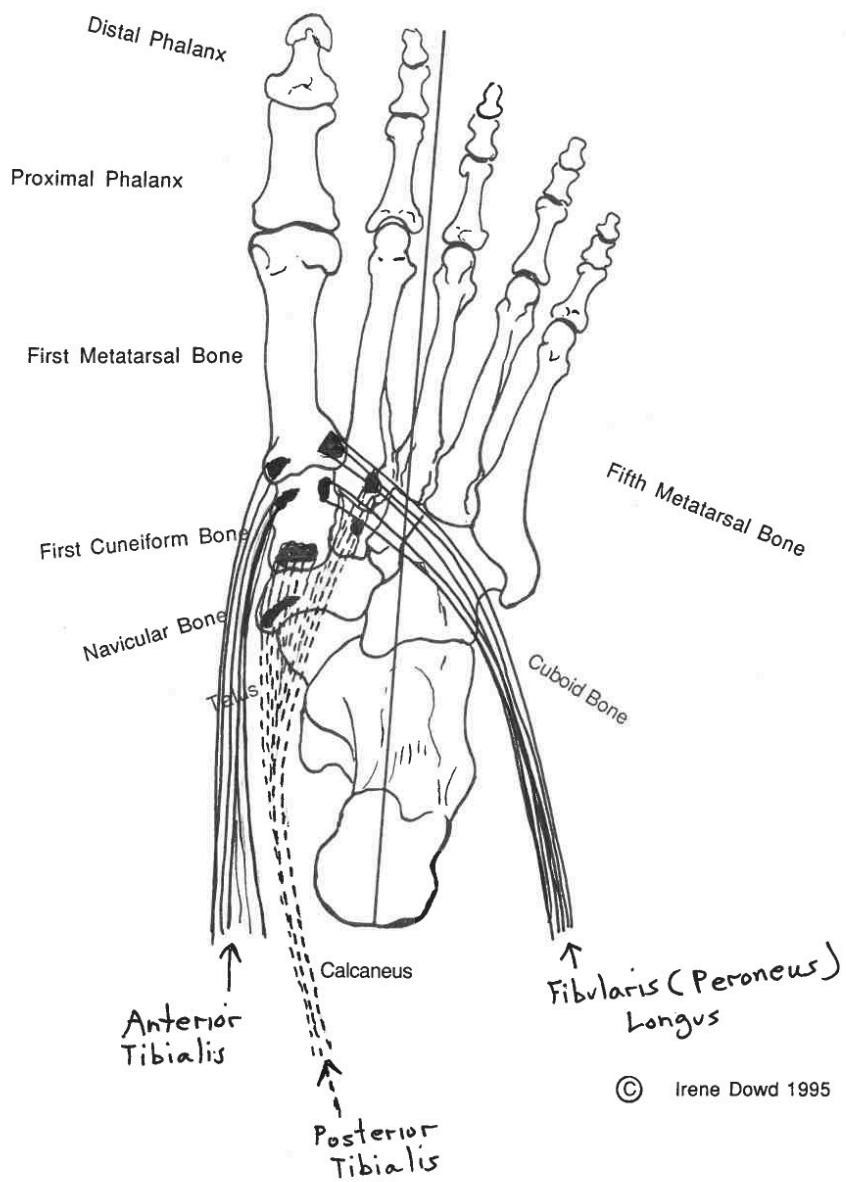
MEDIAL LEG - TENDONS OF MUSCLES FROM POSTERIOR COMPARTMENT  
BOTH SUPERFICIAL AND DEEP



tendons from heel to  
medial malleolus (left to right):

- gastrocnemius & plantaris
- soleus
- flexor hallucis longus
- flexor digitorum longus
- tibialis posterior

Plantar Foot (Bottom View)



# Cross-sectional Schematic of LEFT Lower Leg & Foot

